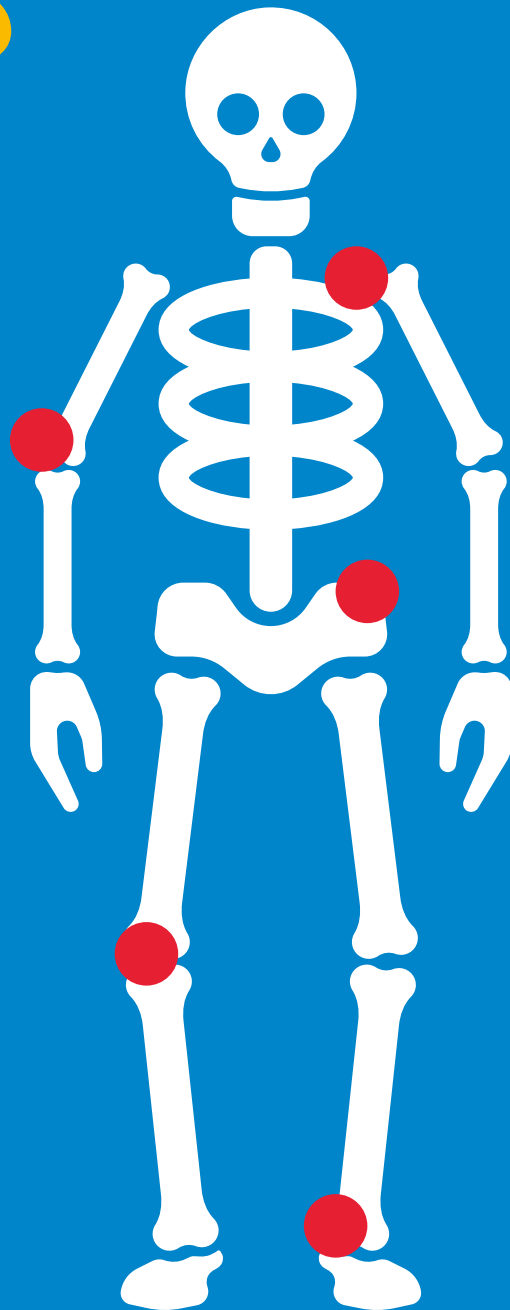


# GUIDE TO THE CLINICAL ASSESSMENT OF PATIENTS WITH MUSCULOSKELETAL CONDITIONS

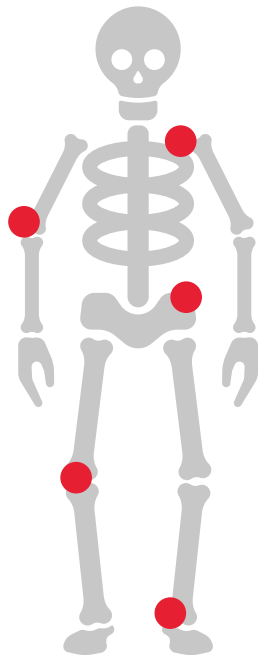


HEALTHCARE  
PROFESSIONALS  
VERSUS  
ARTHRITIS

**WE ARE**  
**VERSUS**  
**ARTHRITIS**

# 18 MILLION PEOPLE IN THE UK LIVE WITH A MUSCULOSKELETAL CONDITION THAT'S THREE IN EVERY TEN PEOPLE

The impact of arthritis can be huge as the condition slowly intrudes on everyday life, affecting the ability to work, to care for a family, to move free from pain and to live independently. Yet arthritis is often dismissed as an inevitable part of ageing or shrugged off as 'just a bit of arthritis'. We don't think that this is OK. Building on the legacies and expertise of both Arthritis Research UK and Arthritis Care, Versus Arthritis is here to change that.



Versus Arthritis is dedicated to stopping the devastating impact that arthritis has on people's lives. When we talk about arthritis, we include all musculoskeletal conditions that affect the joints, bones and muscles – including osteoarthritis, rheumatoid arthritis, back pain and osteoporosis. Although these long-term conditions may be different in pathology, the impact they can have on people's lives is similar. Pain is the most prevalent symptom for people with arthritis, with many experiencing this every day and living with it for years or even decades.

Musculoskeletal conditions are a costly and growing problem. Their prevalence is expected to continue to increase due to our ageing population, rising levels of obesity and physical inactivity. The role of healthcare professionals in enabling people with arthritis to live well, to understand their condition, and to have access to the appropriate information and support to self-manage has never been more important.


Versus Arthritis is here to help you. Our education and training resources for frontline healthcare professionals are accessible, relevant and evidence based. They are designed to support you in confidently diagnosing and managing a range of musculoskeletal conditions, as well as honing your skills in providing patient-centred, holistic care.

Our 'Guide to the clinical assessment of patients with musculoskeletal conditions' has been developed as a study guide for medical, nursing and allied health professional students. It takes a step by step approach to assessing people with musculoskeletal conditions to help you become competent and confident in their care.

# 01.

## ABOUT THIS GUIDE

- 08 BIOGRAPHIES
- 09 FOREWORD
- 09 LIST OF ABBREVIATIONS USED
- 09 TERMINOLOGY
- 09 ACKNOWLEDGEMENTS



# 02.

## INTRODUCTION

- 12 INTRODUCTION TO MUSCULOSKELETAL ASSESSMENT
- 12 INITIAL APPROACH

# 03.


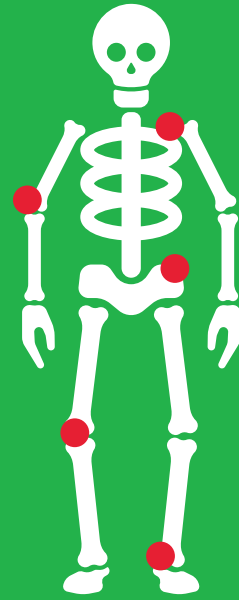
## THE MUSCULOSKELETAL HISTORY

- 16 ARE THE SYMPTOMS FROM THE JOINT OR THE SOFT TISSUES?
- 17 IS THE CONDITION ACUTE OR CHRONIC?
- 18 IS THE CONDITION INFLAMMATORY OR NON-INFLAMMATORY?
- 20 WHAT IS THE PATTERN OF AFFECTED AREAS/JOINTS?
- 22 WHAT IS THE IMPACT OF THE CONDITION ON THE PATIENT'S LIFE?
- 23 ARE OTHER SYSTEMS INVOLVED?



## 04. THE MUSCULOSKELETAL EXAMINATION

- 26 THE MUSCULOSKELETAL SCREEN: 'GALS' QUESTIONS AND EXAMINATION
- 34 PERFORMING A REGIONAL EXAMINATION OF THE MUSCULOSKELETAL SYSTEM 'REMS'




## 05. INVESTIGATIONS

- 50 IMAGING OF BONES AND JOINTS
- 51 BLOOD TESTS
- 51 SYNOVIAL FLUID ANALYSIS

## 06. CONCLUSION

- 54 APPENDIX 1: REVISION CHECKLISTS
- 58 APPENDIX 2: THE CORE SET OF REGIONAL MUSCULOSKELETAL EXAMINATION SKILLS APPROPRIATE FOR A MEDICAL STUDENT AT THE POINT OF QUALIFICATION
- 59 APPENDIX 3: PGALS AND PREMS
- 60 BIBLIOGRAPHY
- 60 ENDORSEMENTS





# 01. ABOUT THIS GUIDE

- 08** **BIOGRAPHIES**
- 09** **FOREWORD**
- 09** **LIST OF ABBREVIATIONS USED**
- 09** **TERMINOLOGY**
- 09** **ACKNOWLEDGEMENTS**

# BIOGRAPHIES



## Author

David Coady is a consultant rheumatologist at Sunderland Royal Hospital. He previously held an Educational Research Fellowship funded by Arthritis Research UK. This focused on identifying the core clinical skills of musculoskeletal examination for undergraduates. He produced the REMS videos which have been used for teaching since 2001. He maintains a keen interest in education, educational research and sailing.



## Medical Editor

Mark Lillicrap is a consultant rheumatologist at Addenbrooke's Hospital in Cambridge and Hinchingsbrooke Hospital in Huntingdon. His interest is in medical education and teaching. He is an associate lecturer and curriculum sub-dean at the University of Cambridge, has led the undergraduate musculoskeletal curriculum in Cambridge, is a lecturer on the Cambridge PGCert in Medical Education and is the director of the undergraduate clinical supervisor programme in Cambridge. Mark has also worked as the director of medical education at Hinchingsbrooke and is a postgraduate educational supervisor for rheumatology specialist trainees.

**DAVID AND MARK HAVE BOTH BEEN CLOSELY INVOLVED IN DEVELOPING PREVIOUS EDITIONS OF THE GUIDE AND HOPE THAT THIS UPDATED VERSION WILL PROVE TO BE A USEFUL RESOURCE FOR EVERYONE INVOLVED IN ASSESSING PATIENTS WITH MUSCULOSKELETAL CONDITIONS.**



# FOREWORD



## Dr Pippa Watson

Consultant Rheumatologist  
and Honorary Senior Lecturer  
University Hospital of  
South Manchester

I'm delighted to introduce the updated Versus Arthritis 'Guide to the clinical assessment of patients with musculoskeletal conditions'. I remember using this guide during my training and finding it to be a clear and useful resource. A few years later I find myself using it again when teaching medical students. I look forward to using this updated version – I think it brilliantly achieves its aim of demystifying examination of the musculoskeletal system, an area which students have previously reported finding difficult.

The guide includes the 'GALS' (Gait, Arms, Legs, Spine) screening examination developed by Professors Paul Dieppe and Mike Doherty. For patients who report symptoms or have positive findings on the GALS screen it offers Regional Examination of the Musculoskeletal System (REMS). The core skills included in REMS are based on a consensus reached across a broad spectrum of UK clinicians in a study led by Dr David Coady. Regional examinations are structured using the look/feel/move/function approach making them easy to recall and perform.

This new edition focuses on examination, but also includes tips on history taking and investigations that will assist in making a diagnosis. It also includes paediatric examination incorporating work led by Professor Helen Foster which led to the development of paediatric versions pGALS and pREMS. These are based on the adult examinations with additions to improve detection and identification of musculoskeletal problems in school-aged children.

I hope you will enjoy it and find it useful too. Over to you – time to get reading and then practising!

## List of abbreviations used

- CMC(J)** carpometacarpal (joint)
- CT** computerised tomography
- DEXA** dual-energy x-ray absorptiometry
- DIP(J)** distal interphalangeal (joint)
- ESR** erythrocyte sedimentation rate
- GALS** gait, arms, legs and spine
- MCP(J)** metacarpophalangeal (joint)
- MRI** magnetic resonance imaging
- MTP(J)** metatarsophalangeal (joint)
- NSAIDs** non-steroidal anti-inflammatory drugs
- OA** osteoarthritis
- PIP(J)** proximal interphalangeal (joint)
- RA** rheumatoid arthritis
- REMS** regional examination of the musculoskeletal system

## Terminology

It could be argued that the term 'arthritis' should only be used to describe inflammatory disorders of the joint whilst 'arthropathy' should be used to describe non-inflammatory disorders of the joint. However, the term 'arthritis' is in such widespread use to describe any disorder of the joint that, for the purpose of this guide, it will be used in that sense.

## Acknowledgements

We remain indebted to Professor Paul Dieppe – his earlier version of this guide has been widely referred to by medical students in the UK since 1991 and his text remains influential in this new edition.

We would like to thank David Coady and Mark Lillcrap for their considerable time and commitment in updating the content, Pippa Watson for her feedback and additional support during the filming of the video material, and all those who took the time to comment on the previous edition and early drafts of the new guide – Onebieni Ana, Ivan Cheuk Li, Nathan Ng, Jamie Nicholson, Sarah-Jane Ryan, Sophia Wakefield, Louise Warburton and Anita Williams.



# 02. INTRODUCTION

**12** **INTRODUCTION TO  
MUSCULOSKELETAL  
ASSESSMENT**

**12** **INITIAL APPROACH**

# INTRODUCTION TO MUSCULOSKELETAL ASSESSMENT

It is estimated that musculoskeletal disorders account for approximately 30 per cent of a GP's workload (Department of Health, 2006) and are the most common cause of repeat consultations in primary care. About 30 per cent of those with any physical disability, and 60 per cent of those with a severe disability, have a musculoskeletal disorder as the primary cause of their problems.

Clinical assessment skills – i.e. history taking and examination – are the key to making an accurate diagnosis and appropriately managing any patient presenting with a musculoskeletal problem. This guide aims to introduce you to the methods you might use during the initial clinical assessment. It is not exhaustive or intended to replace direct clinical teaching and experience, but to be used as an aid to learning.

# INITIAL APPROACH

Before considering a diagnosis, it is useful to try to broadly categorise the symptoms and signs (from the history and examination) by answering the following key questions:

- Are the symptoms from the joint itself or the soft tissues (tendons/muscles)?
- Is the condition acute or chronic?
- Is the condition inflammatory or non-inflammatory?
- What is the pattern of affected areas/joints?
- What is the impact of the condition on the patient's life?
- Are other systems involved?

The answers to these questions should enable you to produce a succinct summary of the patient's condition and would lead you to a narrower differential diagnosis. An example of a patient summary produced using this method might be:

**'This patient has a chronic symmetrical inflammatory polyarthritis, mainly affecting the small joints of the hands and feet, which is causing pain, difficulty with dressing and hygiene, and is limiting their mobility.'**




---



---



---



---



---



---



---



---



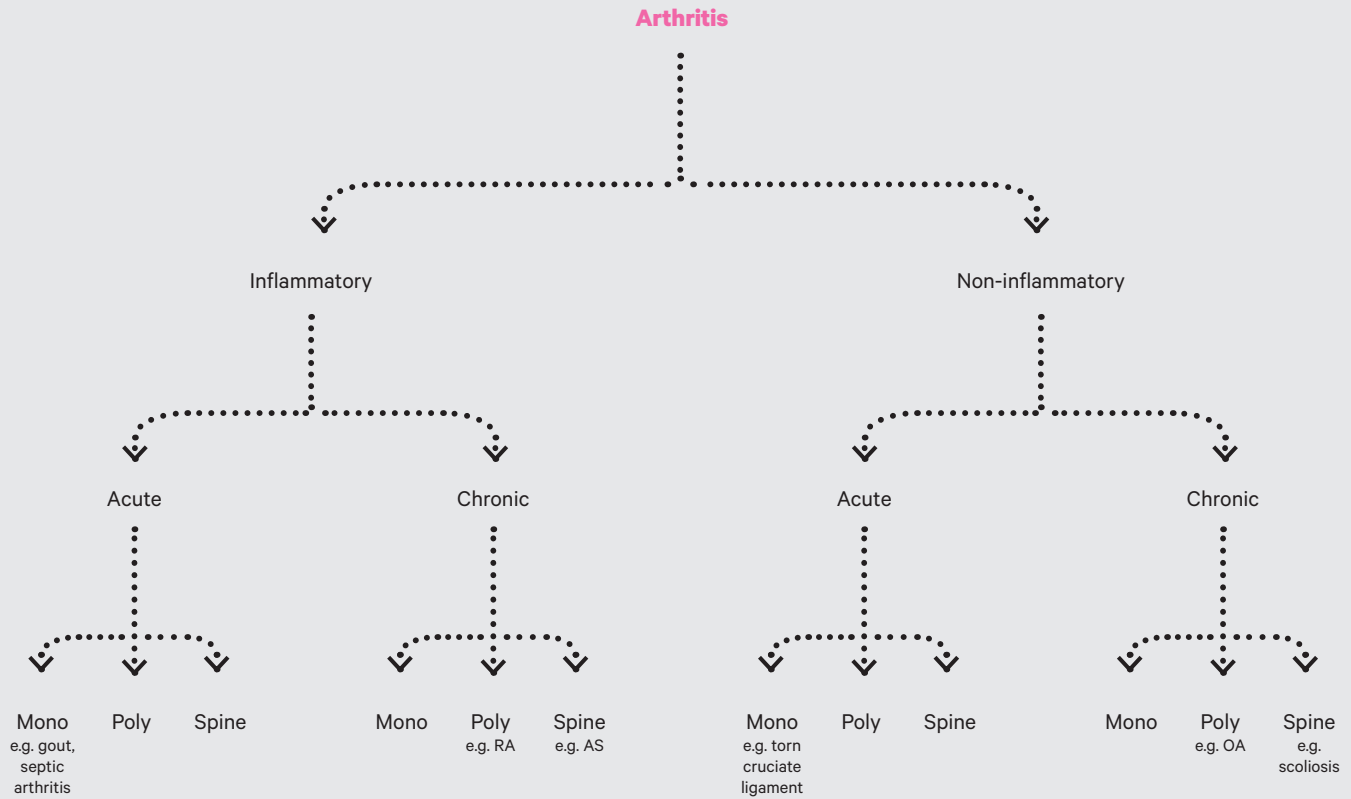
---



---

Figure 1.

**Classification of the arthritides:**  
 Mono = monoarticular (one joint);  
 Poly = polyarticular (several joints)





**03.  
THE  
MUSCULOSKELETAL  
HISTORY**

- 16** ARE THE SYMPTOMS FROM THE JOINT OR THE SOFT TISSUES?
- 17** IS THE CONDITION ACUTE OR CHRONIC?
- 18** IS THE CONDITION INFLAMMATORY OR NON-INFLAMMATORY?
- 20** WHAT IS THE PATTERN OF AFFECTED AREAS/JOINTS?
- 22** WHAT IS THE IMPACT OF THE CONDITION ON THE PATIENT'S LIFE?
- 23** ARE OTHER SYSTEMS INVOLVED?

# THE MUSCULOSKELETAL HISTORY

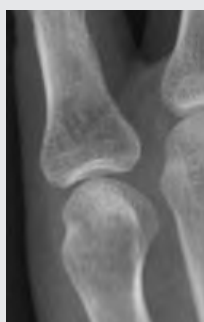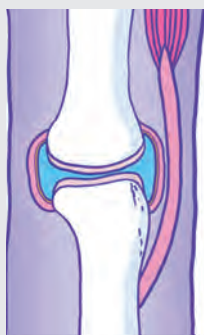
# ARE THE SYMPTOMS FROM THE JOINT OR THE SOFT TISSUES?

**Clinical communication skills (of which history taking is one part) are among the most important skills for any healthcare practitioner to acquire – this can only be achieved through regular practice. A good history backed up by clinical examination findings will lead you to a diagnosis. Below we look more closely at the key questions that need to be addressed.**

This guide is primarily concerned with problems arising from the joints – that is from the articular and periarticular structures. (These structures are shown in Figure 2, while Figures 3a and 3b represent diagrammatically the changes that occur in the two main types of arthritis). However, it is important to identify those cases where pain may appear to arise from the joint but is in fact referred pain – for example, where the patient describes pain in the left shoulder, which might in fact be referred pain from the diaphragm, the neck, or perhaps ischaemic cardiac pain. In cases where examination reveals no abnormalities in the joint, other clues will be obtained by taking a thorough history. A common cause of widespread pain with normal joint examination for example is fibromyalgia.

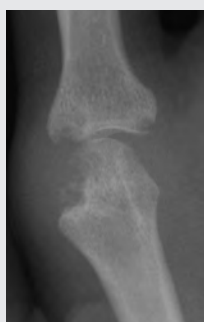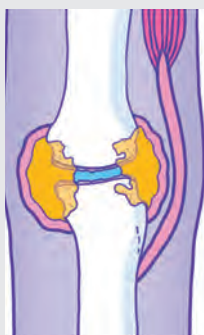**Figure 2.**  
X-ray and cross-sectional diagram of a synovial joint and its periarticular structures

- Normal joint space made up of cartilage
- Smooth bone contours



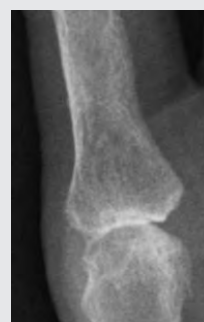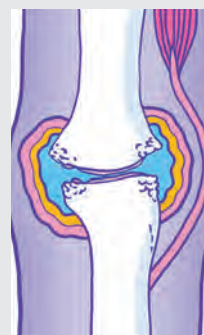
**Figure 3a.**  
X-ray and diagrammatic representation of an index finger MCP joint affected by rheumatoid arthritis.

- Osteopenia (bone loss)
- Loss of joint space
- Erosions



**Figure 3b.**  
X-ray and diagrammatic representation of an index finger MCP joint affected by osteoarthritis.

- Sclerosis (thickening of bone)
- Joint space loss (Cartilage loss)
- Osteophyte formation (extra bone growth)





# IS THE CONDITION ACUTE OR CHRONIC?

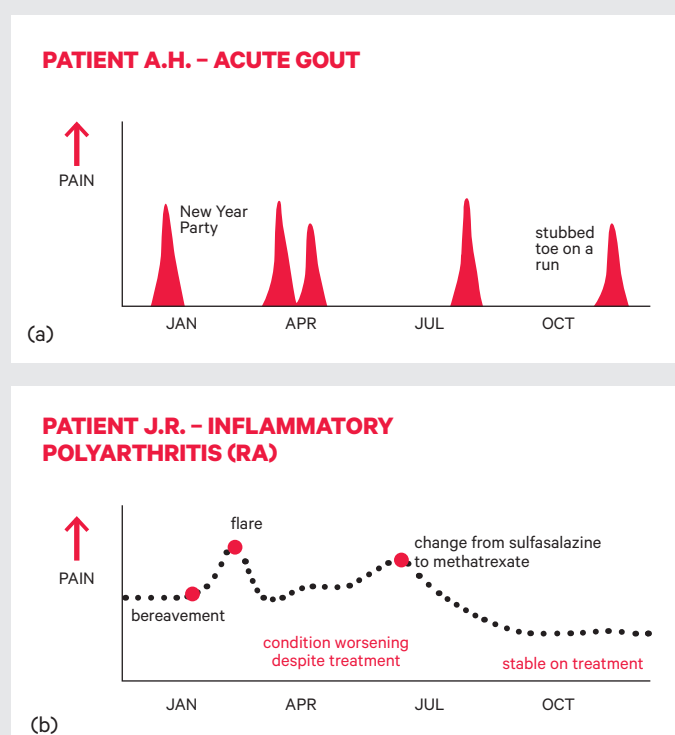
You will need to listen to the patient's history to find out:

- When did the symptoms start and how have they evolved? Was the onset sudden or gradual?
- Was the onset associated with a particular event – for example, trauma or infection?
- Which treatments has the condition responded to?

The way in which symptoms evolve and respond to treatment can be an important guide in making a diagnosis. Gout, for example, is characterised by acute attacks – these often start in the middle of the night, become excruciatingly painful within a few hours, and respond well to non-steroidal anti-inflammatory drugs (NSAIDs).

Musculoskeletal symptoms lasting more than six weeks are generally described as chronic. Chronic diseases may start insidiously and may have a variable course with remissions and exacerbations influenced by therapy and other factors. It may be helpful to represent the chronology of a condition graphically (see Figure 4).

**Figure 4.**  
**Graphs representing the chronology of a condition:**  
 (a) for a patient with gout; (b) for a patient with rheumatoid arthritis.





### Stiffness

In general, inflammatory arthritis is associated with prolonged morning stiffness which is generalised and may last for several hours. The duration of the morning stiffness is a rough guide to the activity of the inflammation.

Non-inflammatory arthritis, such as osteoarthritis of the knee, tends to cause localised stiffness which may be short-lasting (less than 30 minutes) but can recur after sitting for short periods.

With inflammatory diseases such as rheumatoid arthritis, where joint destruction occurs over a prolonged period, the inflammatory component may eventually become less active and give way to secondary mechanical pain as a result of the damage. It is therefore sometimes difficult for patients to distinguish between pain and stiffness, so your questions will need to be specific.

### Joint swelling

A history of joint swelling, especially if it is intermittent, is normally a good indication of an inflammatory disease process. Patients often describe rings becoming tight or a sensation of walking on pebbles.

There are exceptions however. Nodal osteoarthritis, for example, causes bony, hard and non-tender swelling in the proximal interphalangeal (PIP) and distal interphalangeal (DIP) joints of the fingers. Swelling of the knee is also less suggestive of inflammatory disease as it can also occur with trauma and in OA. Ankle swelling is a common complaint, but this is more commonly due to oedema than to swelling of the joint.

**Box 1.**  
**Features of inflammatory cf.**  
**degenerative symptoms**



# WHAT IS THE PATTERN OF AFFECTED AREAS/JOINTS?

The pattern of joint involvement is very helpful in defining the type of arthritis, as different patterns are associated with different diseases.

## Common patterns of joint involvement include:

**Monoarticular** – only one joint affected (e.g. septic arthritis)

**Pauciarticular** (or oligoarticular) – only a few joints affected (e.g. psoriatic arthritis)

**Polyarticular** – many joints affected (e.g. rheumatoid arthritis)

**Axial** – the spine is predominantly affected (e.g. ankylosing spondylitis)

As well as the **number of joints affected**, it is useful to consider whether the **large or small joints** are involved, and whether the pattern is **symmetrical or asymmetrical**. Rheumatoid arthritis, for example, is a polyarthritis (it affects lots of joints) that tends to be symmetrical (if it affects one joint, it will affect the same joint on the other side), and if it affects one of a group of joints it will often affect them all, for example, the metacarpophalangeal (MCP) joints.

Note, however, that this describes established disease and early RA can affect any pattern of joints.

Spondyloarthritides, such as psoriatic arthritis, are more likely to be asymmetrical and may be associated with inflammatory symptoms, such as early morning stiffness involving the spine.

Osteoarthritis tends to affect weight-bearing joints and the parts of the spine that move most (lumbar and cervical).

Table 1 provides a summary of typical features of some common musculoskeletal conditions.




---



---



---



---



---



---



---



---



---



---

**Table 1.**  
What to look for: diagnostic tips

	Common inflammatory conditions				Common non-inflammatory conditions	
	Rheumatoid arthritis (RA)	Seronegative arthritides (e.g. reactive and psoriatic arthritis)	Gout	Polymyalgia rheumatica (PMR)	Osteoarthritis (OA)	Fibromyalgia
Onset	Usually acute or subacute	Acute/subacute Or chronic	Usually acute	Usually acute/ subacute	Chronic	Chronic
Typical age and gender	Female: male 3:1  Any age	Any age	Female: male 1:3  Very rare in pre-menopausal women	Female: male 2:1	Hand OA more common in females  Usually age ≥45	Female: male 7:1  Age 30–50
Pattern of joint involvement	Usually symmetrical hands and feet	Can be monoarthritis or asymmetrical polyarthritis or spine	Monoarthritis most commonly – MTP, ankle, knee	Usually shoulder and pelvic girdle	Normally polyarticular  Hands, knees, hip and feet most common	Widespread pain
Other clues	Raynaud's syndrome  Dry eyes and mouth  Systemic upset	Tendon insertion pain (enthesitis)  Psoriasis  Inflammatory bowel disease  Uveitis	Risk factors: obesity, alcohol, diuretic treatment	Severe stiffness  May have overlap lap with temporal arteritis	Heberden's or Bouchard's nodes  Crepitus	Poor quality of sleep  Tender soft tissue 'trigger points' on examination  Multiple symptoms

# WHAT IS THE IMPACT OF THE CONDITION ON THE PATIENT'S LIFE?

**Understanding the impact of the disease on the patient is crucial to negotiating a suitable management plan.**

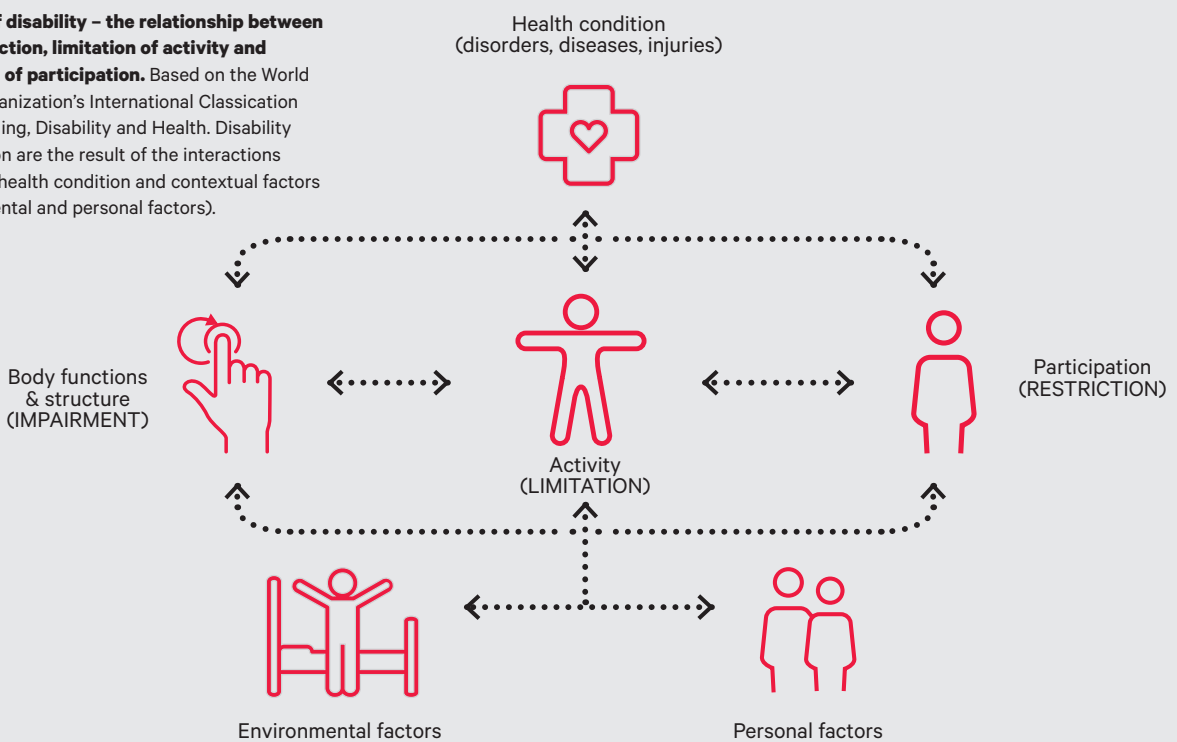
Ask open-ended questions about functional issues and difficulty with day-to-day activities. It may be easiest to get the patient to describe a typical day, from getting out of bed to washing, dressing, toileting etc. Potentially sensitive areas – such as hygiene or sexual activity, mood, depression and anxiety – should be approached with simple, direct, open questions. The impact of the disease on the patient's employment will be crucial.

A patient's needs and aspirations are an important part of the equation and will influence their ability to adapt to the condition. Questioning around the things a person would like to do, but is currently unable to, may pinpoint key issues. What are

their ideas, concerns and expectations? Later negotiations with the patient on balancing the risks and benefits of an intervention will be greatly affected by the patient's priorities.

All healthcare practitioners should have an awareness of the relationship between functional loss, limitation of activity, and restriction of participation as indicated in the World Health Organization's International Classification of Functioning, Disability and Health (see Figure 5). Being unable to fully flex a finger (loss of function) might lead to difficulty, for example, with fastening buttons (activity) which might have a minor impact on general life (participation). The same loss of function, however, might prevent a pianist from playing (activity) which, for a professional musician, might have a significant impact on his/her way of life (participation). (see Figure 5).

**Figure 5.** A model of disability – the relationship between loss of function, limitation of activity and restriction of participation. Based on the World Health Organization's International Classification of Functioning, Disability and Health. Disability and function are the result of the interactions between a health condition and contextual factors (environmental and personal factors).



# ARE OTHER SYSTEMS INVOLVED?

Inflammatory arthritis often involves other systems including the skin, eyes, lungs and kidneys. In addition, patients with inflammatory disease often suffer from general symptoms such as malaise, weight loss, mild fevers and night sweats. Osteoarthritis, in contrast, is limited to the musculoskeletal system and is not associated with immune activation. Systemic symptoms would therefore not be expected.

Fatigue and depression may be common in any arthritis where there is functional loss or chronic pain. A comprehensive history must include the usual screening questions for all systems as well as specific enquiries relating to known complications of specific musculoskeletal disorders.

Arthritis may occur on a background of other illnesses and it is important to consider other ongoing health issues, particularly with an increasingly ageing population. A combination of two problems will be worse than either one alone, and the impact on the patient will therefore be greater. In addition, other conditions may be affected by the treatments prescribed for the arthritis – for example, the presence of liver disease may limit the use of disease-modifying drugs for inflammatory arthritis, because most of these drugs can upset the liver.



---

---

---

---

---

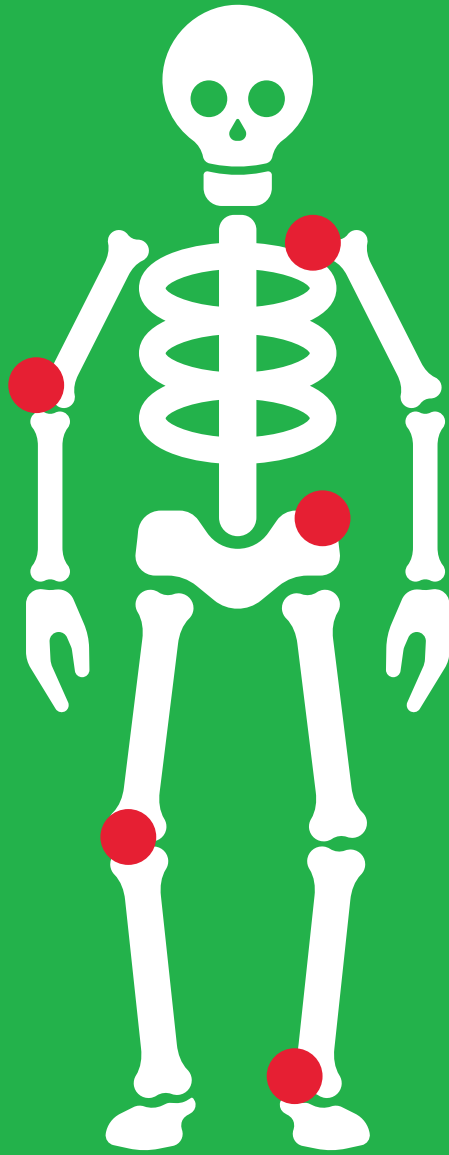
---

---

---

---

---



**04.  
THE  
MUSCULOSKELETAL  
EXAMINATION**



**26** **THE MUSCULOSKELETAL  
SCREEN: 'GALS' QUESTIONS AND  
EXAMINATION**

**34** **PERFORMING A REGIONAL  
EXAMINATION OF THE  
MUSCULOSKELETAL SYSTEM  
'REMS'**

# THE MUSCULOSKELETAL SCREEN: 'GALS' QUESTIONS AND EXAMINATION

**So far, the discussions of history taking above have assumed that the patient has come to see you with joint-related pain. However, it is also important to make a routine assessment of any musculoskeletal problems irrespective of their presenting symptoms.**

The GALS – Gait, Arms, Legs and Spine – screen consists of three simple questions and a brief examination developed to detect significant musculoskeletal abnormalities (Doherty et al, 1992). It can also be used as a screening tool prior to a more focused examination.

## Routine screening questions

Screening questions that assess the musculoskeletal system should be incorporated into the routine systemic enquiry of every patient. As discussed, the main symptoms arising from disorders of the musculoskeletal system are pain, stiffness, swelling, and associated functional problems. The screening questions we use to directly address these areas are:

Question	Rationale
Do you have any pain, swelling or stiffness in your muscles, joints or back?	focuses on the common symptoms of a musculoskeletal problem
Can you dress yourself completely without any difficulty?	focuses on upper limb function
Can you walk up and down stairs without any difficulty?	focuses on lower limb function

A patient who has no pain or stiffness, and no difficulty with dressing or with climbing stairs is unlikely to be suffering from any significant musculoskeletal disorder. If the patient does have pain or stiffness, or difficulty with either of these activities, then a more detailed history should be taken.



Watch the real time run through and step by step GALS examination videos.

[www.versusarthritis.org/GALSexamination](http://www.versusarthritis.org/GALSexamination)



# THE SCREENING EXAMINATION ('GALS')

**This examination was devised for use in routine clinical assessment and takes 1-2 minutes to perform. It involves inspecting carefully for joint swelling and abnormal posture, as well as assessing the joints for normal movement.**

If an abnormality of an individual area is noted in the GALS screen, that area should be examined in more detail using the relevant regional examination routine (REMS). The GALS screen is not designed to tell you what the problem is, only that there is a problem that requires further assessment.

The sequence in which these four elements (**Gait, Arms, Legs and Spine**) are assessed can be varied – in practice, it is usually more convenient to complete the elements for which the patient is standing before asking the patient to lie onto the couch.

### Introduction

It is important to introduce yourself, explain to the patient what you are going to do, gain verbal consent to examine, and ask the patient to let you know if you cause them any pain or discomfort at any time. In all cases it is important to make the patient feel comfortable about being examined and this extends to the clothing they wear and level of exposure.

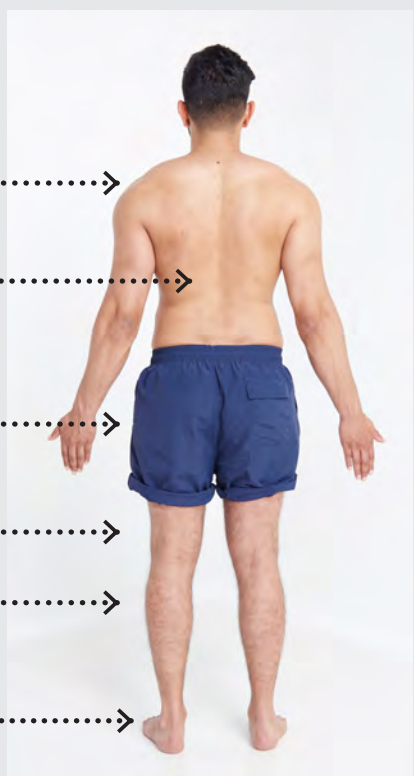A good musculoskeletal examination relies on patient cooperation, in order for them to relax their muscles, but also the ability to view and compare joints and muscle groups if important clinical signs are not to be missed.

**FIGURE 6.** With the patient in the anatomical position, observe from behind, from the side, and from the front, checking for:

- Full elbow extension
- Quadriceps bulk and symmetry
- Forefoot abnormalities



- Shoulder muscle bulk and symmetry
- Spinal alignment
- Gluteal muscle bulk and symmetry
- Popliteal swelling or abnormalities
- Calf muscle bulk and symmetry
- Hindfoot abnormalities



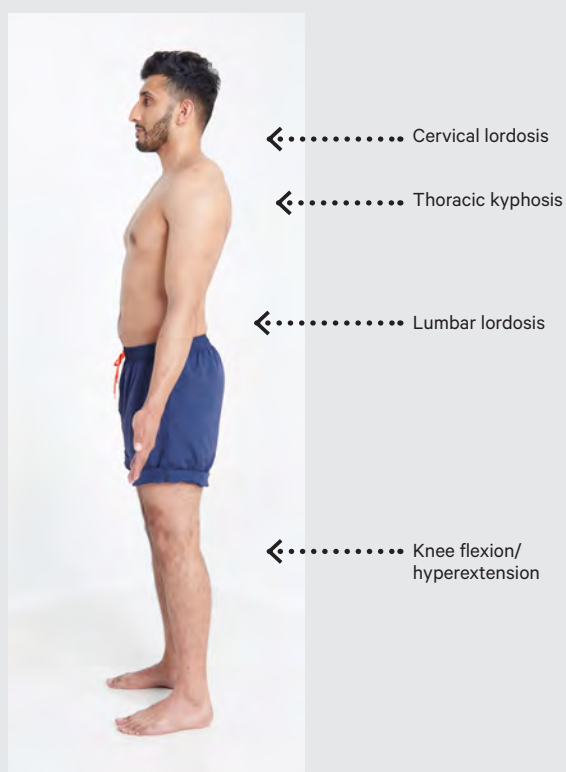

Watch the real time run through and step by step GALS examination videos.

[www.versusarthritis.org/GALSExamination](http://www.versusarthritis.org/GALSExamination)

### Gait

- Ask the patient to walk a few steps, turn and walk back. Observe the patient's gait for symmetry, smoothness and the ability to turn quickly.
- With the patient standing in the anatomical position, observe from behind, from the side, and from in front for:
  - bulk and symmetry of the shoulder, gluteal, quadriceps and calf muscles
  - limb alignment
  - alignment of the spine
  - equal level of the iliac crests
  - ability to fully extend the elbows and knees
- popliteal swelling
- abnormalities in the feet such as an excessively high or low arch profile, clawing/retraction of the toes and/or presence of hallux valgus (see Figure 6).



**1 TO 2  
MINUTES  
EXAMINATION  
TIME**

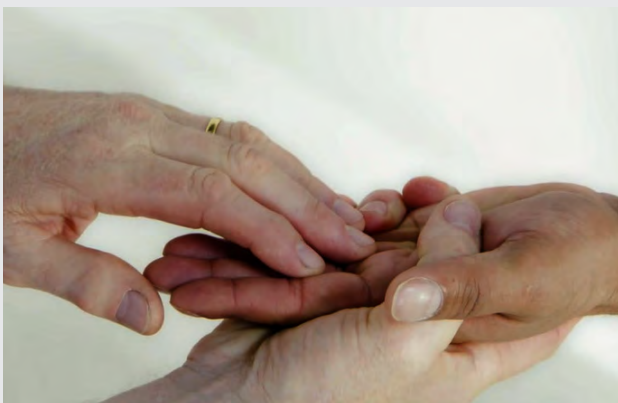# THE SCREENING EXAMINATION ('GALS')

## Arms

- Ask the patient to put their hands behind their head. This assesses shoulder abduction (the first movement affected by rotator cuff problems) and external rotation (the first movement affected by glenohumeral problems). It also assesses elbow flexion.
- Ask the patient to straighten out their arms completely to assess full elbow extension (the first movement affected by elbow problems).
- With the patient's hands held out, palms down, fingers outstretched, observe the backs of the hands for joint swelling and deformity. Inspect the nails and skin at the same time.
- Ask the patient to turn their hands over (the movement of supination assesses both wrist and elbow movement).
- Look at the palms for muscle bulk and for any visual signs of abnormality.
- Ask the patient to make a fist. Visually assess power grip, hand and wrist function, and range of movement in the fingers.
- Ask the patient to squeeze your fingers. Assess grip strength.
- Ask the patient to bring each finger in turn to meet the thumb. Assess fine precision pinch (which is important functionally).
- Gently squeeze across the metacarpophalangeal (MCP) joints to check for tenderness suggesting inflammation within the joints (see figure 7). (Be sure to watch the patient's face for non-verbal signs of discomfort.)

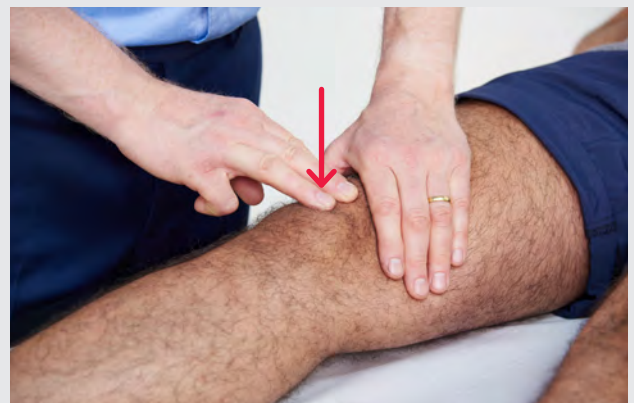**FIGURE 7.**

**MCP squeeze test.** Gently squeeze across the metacarpophalangeal joints to check for tenderness suggesting inflammation within the joints.



**FIGURE 8.**

**Patellar tap test.** Slide your hand down the patient's thigh, compressing the suprapatellar pouch. This forces any effusion behind the patellar. With two or three fingers of the other hand, push the patella down gently. In a positive test the patella will bounce and tap.





Watch the real time run through and step by step GALS examination videos.

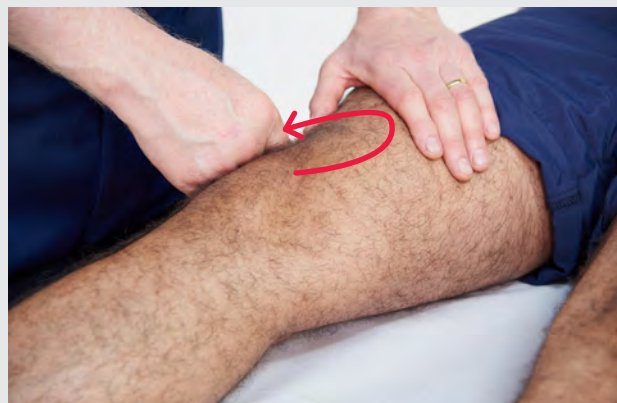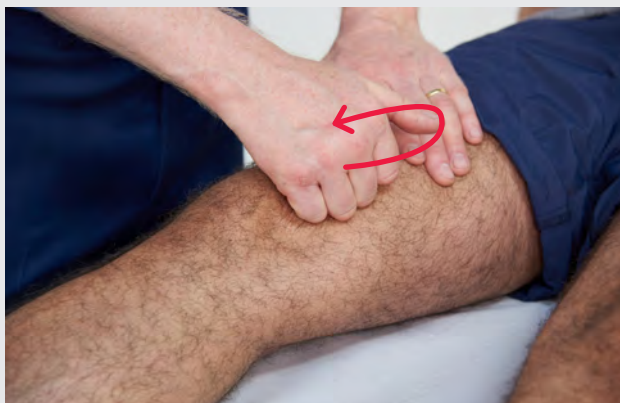[www.versusarthritis.org/GALSExamination](http://www.versusarthritis.org/GALSExamination)

## Legs

- With the patient lying on the couch, assess full flexion and extension of both knees, feeling over the tibiofemoral joint line for crepitus during the movements.
- With the hip and knee flexed to 90°, holding the knee and ankle to guide the movement, assess internal rotation of each hip in flexion (this is often the first movement affected by hip problems).
- Perform a check for a knee effusion using either a patellar tap or a sweep/bulge test:
  - For a patellar tap, slide your hand down the thigh, pushing down over the suprapatellar pouch so that any effusion is forced behind the patella. When you reach the upper pole of the patella, keep your hand there and maintain pressure. Use two or three fingers of the other hand to push the patella down gently (see Figure 8). Does it bounce and ‘tap’? This indicates the presence of a relatively large effusion.
  - Small effusions may not be detected with the patella tap test and a sweep/bulge test may be useful. For a sweep/bulge test, stroke the medial side of the knee upwards (towards the suprapatellar pouch) to empty the medial compartment of fluid, then stroke the lateral side downwards (distally) (see Figure 9). The medial side may refill and produce a bulge of fluid indicating an effusion.
- From the end of the couch, inspect the feet for localised or general swelling, deformity such as hallux valgus, clawing of the toes, and callosities on the soles which typically occur under the metatarsophalangeal joints (MTP).
- Squeeze across the metatarsophalangeal (MTP) joints to check for tenderness suggesting inflammatory joint disease. (Be sure to watch the patient’s face for signs of discomfort.)

**FIGURE 9.**

**Sweep/bulge test.** Stroke the medial side of the knee upwards towards the suprapatellar pouch. This empties the medial compartment of fluid. The stroke the lateral side downwards (distally). The medial side may refill and produce a bulge of fluid, indicating the presence of an effusion.



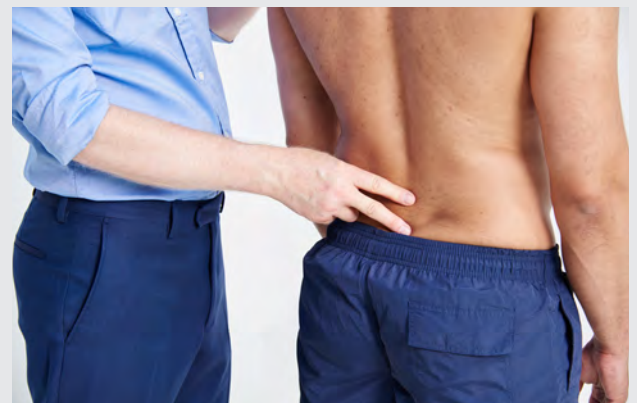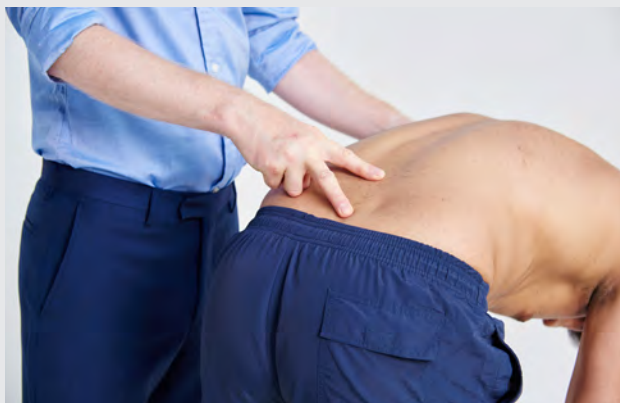# THE SCREENING EXAMINATION ('GALS')

## Spine

- With the patient standing, inspect the spine from behind for evidence of scoliosis, and from the side for abnormal lordosis or kyphosis. Note any obvious asymmetry by looking from behind initially at the shoulders, then the pelvis, the backs of the knees and then the ankle.
- Ask the patient to tilt their head to each side, bringing the ear towards the shoulder. This assesses lateral flexion of the neck, which is sensitive in the detection of early neck problems.
- Ask the patient to bend to touch their toes. This movement is the first movement affected by lumbar spinal problems and is important functionally (for dressing). However, it can be achieved by relying on good hip flexion, so it is important to palpate for normal movement of the vertebrae. Assess lumbar spine flexion by placing two or three fingers on the lumbar vertebrae. Your fingers should move apart on flexion and back together on extension (see Figure 10).

**Figure 10.**

**Assessing lumbar spine flexion.** Place two or three fingers on the lumbar vertebrae. Your fingers should move apart on flexion and back together on extension.





### Recording the findings from the screening examination (GALS)

It is important to record both positive and negative findings in the notes. The presence or absence of changes – in appearance or movement – in the gait, arms, legs or spine should be recorded. For a normal result 'GALS: NAD' is sufficient. If there are abnormalities such as swelling or restriction of movement, these should be recorded with a brief descriptive note.

If you have been alerted to a musculoskeletal problem – by the screening questions, your examination or the spontaneous complaints of the patient – you will need to take a detailed history (as described above). You should also conduct a regional examination of relevant joints – this is described in the sections that follow.



---

---

---

---

---

---

---

---

---

---

---

# PERFORMING A REGIONAL EXAMINATION OF THE MUSCULOSKELETAL SYSTEM ('REMS')

Regional examination of the musculoskeletal system refers to the more detailed examination that should be carried out once an abnormality has been detected either through the history or through the screening examination (GALS). REMS involves the examination of a group of joints that are linked by function, and may sometimes require a detailed neurological and vascular examination.

REMS was born out of a desire to standardise and simplify examination of the musculoskeletal system, allowing for more systematic teaching and learning for medical students. It is now being used more widely within medical practice and members of the wider musculoskeletal team. It was developed through a national consensus process involving UK consultants in rheumatology, orthopaedics and care of the elderly, and selected general practitioners (Coady et al, 2004). It led to an agreed set of 'core' skills (see Appendix 2).

**For the purposes of this guide (and the accompanying videos) the REMS examination has been divided into seven areas, each of which is described in detail below.**

However, it should be remembered that this is an artificial division and that one group of joints may need to be examined in conjunction with another group (e.g. the shoulder and cervical spine).

There are some key stages which need to be completed during an examination of the joints in any part of the body:

- Introduce yourself.
- Look at the joint(s).
- Feel the joint(s).
- Move the joint(s).
- Test function of the joint(s).
- Perform special tests if relevant.

## Introduce yourself

As highlighted in the GALS screening assessment, it is important to introduce yourself, explain to the patient what you are going to do (and why), gain verbal consent to examine, and ask the patient to let you know if you cause them any pain or discomfort at any time.



### Look

The examination should always start with a visual inspection of the exposed area at rest. Compare one side with the other, checking for symmetry. You should look specifically for skin changes, muscle bulk, and swelling in and around the joint. Look also for deformity in terms of alignment and posture of the joint.



### Feel

Using the back of your hand, feel for skin temperature across the joint line and at relevant neighbouring sites. Any swellings should be assessed for fluctuance and mobility. The hard, bony swellings of osteoarthritis should be distinguished from the soft, rubbery swellings of inflammatory joint disease. Tenderness is an important clinical sign to elicit – both in and around the joint. Identifying inflammation of a joint (synovitis) relies on detecting the triad of warmth, swelling and tenderness.



Watch the video introducing how to perform a regional examination of the musculoskeletal system:

[www.versusarthritis.org/introductiontoREMS](http://www.versusarthritis.org/introductiontoREMS)



### Move

The full range of movement of the joint should be assessed. Compare one side with the other. Generally, both active movements (where the patient moves the joint themselves) and passive movements (where the examiner moves the joint) should be performed. If there is a loss of active movement, but passive movement is unaffected, this may suggest a problem with the muscles, tendons or nerves rather than the joints themselves, or it may be an effect of pain in the joints. In certain instances, joints may move further than expected – this is called hypermobility.

It is important to elicit a loss of full flexion or a loss of full extension as either may affect function. A loss of movement should be recorded as mild, moderate or severe. Specialists may often document how many degrees of movement are restricted since this allows future comparison to be made. The quality of movement should also be recorded, with reference to abnormalities such as increased muscle tone or the presence of crepitus. With experience it is possible to assess the quality particularly at the extremes or ‘end range’ of movement. A degenerative joint often has a more solid ‘end feel’.



### Function

It is important to make a functional assessment of the joint – for example, in the case of limited elbow flexion, does this make it difficult for the patient to bring their hands to their mouth? In the case of the lower limbs, function mainly involves gait and the patient’s ability to get out of a chair and walk.

#### Special tests

Several additional tests may be used by experienced musculoskeletal practitioners as an adjunct to the REMS examination. Known as ‘special tests’, these are often performed towards the end of the examination and would follow on from ‘Move’ and ‘Function’.

Covering all possible tests, including their specificity and sensitivity in different scenarios, is beyond the scope of this guide. However, a small number of tests that may be appropriate for undergraduates have been included and highlighted in the sections that follow.




---



---



---



---



---



---

# EXAMINATION OF THE HAND AND WRIST

**This should normally take place with the patient's forearms exposed to above the elbows. The patient's hands should be resting on a pillow as it can be painful for patients with elbow or shoulder problems to hold their hands up for long periods.**



## Look

**With the patient's hands palms down:**

- Look at the posture and check for obvious swelling, deformity, muscle wasting and scars.
- Look at the skin for thinning and bruising (possible signs of long-term steroid use) or rashes.
- Look at the nails for psoriatic changes such as pitting or onycholysis (see Figure 11), and evidence of nailfold vasculitis.
- Decide whether the changes are symmetrical or asymmetrical.
- Do the changes mainly involve the small joints (PIPs and DIPs, MCPs etc) or the wrists?

It is often helpful to structure the inspection from proximal to distal to ensure that all areas are systematically assessed.

**Ask the patient to turn their hands over:**

- Does the patient have problems with this due to proximal or distal radioulnar joint involvement?

**With the patient's hands palms up:**

- Look again for muscle wasting – if present, is it in both the thenar and hypothenar eminences? If it is only in the thenar eminence, then perhaps the patient has carpal tunnel syndrome. Look for signs of palmar erythema. Look at the wrist for a carpal tunnel release scar.
- Look at the elbow for rheumatoid nodules, psoriatic plaques and surgical scars.



## Feel

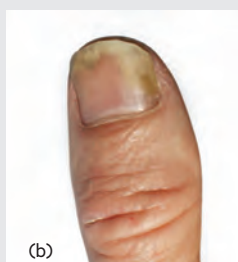
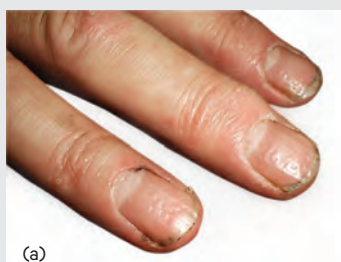
**With the patient's hands palms up:**

- Feel for peripheral pulses (ischaemia could be causing pain).
- Feel for bulk of the thenar and hypothenar eminences and for tendon thickening.
- Assess median and ulnar nerve sensation by gently touching over both the thenar and hypothenar eminences, and the index and little fingers respectively – if not normal and equal, this may indicate an entrapment neuropathy.

**Ask the patient to turn their hands back over, so their palms are face down:**

- Assess radial nerve sensation by light touch over the thumb and index finger web space.
- Using the back of your hand, assess skin temperature at the patient's forearm, wrist and MCP joints. Are there differences?

**FIGURE 11.** Fingernails affected by psoriasis: (a) pitting; (b) onycholysis





Watch the hand and wrist examination video:

[www.versusarthritis.org/handandwristexamination](http://www.versusarthritis.org/handandwristexamination)

- Gently squeeze across the row of MCP joints to assess for tenderness (watching the patient's face for signs of discomfort).
- Bimanually palpate any MCP joints and any PIP or DIP joints that appear swollen or painful. Is there evidence of active synovitis? (The joints will be warm, swollen and tender and may have a 'rubbery' feel, or you may even detect effusions).
- Are there hard, bony swellings? Check for squaring of the carpometacarpal (CMC) joint of the thumb and for Heberden's nodes on the DIPs. There may be evidence of previous synovitis (thickened, rubbery but non-tender joints).
- Compare one joint with another, or with your own, to decide whether the small joints are normal.
- Bimanually palpate the patient's wrists.
- Finally run your hand up the patient's arm along the ulnar border to the elbow. Feel and look for rheumatoid nodules or psoriatic plaques on the extensor surfaces.



### Move

- Ask the patient to straighten their fingers fully (against gravity). If the patient is unable to do this it may be due to joint disease, extensor tendon rupture or neurological damage – this can be assessed by moving the fingers passively.
- Ask the patient to make a fist. If they have difficulty

tucking the fingers into the palm, this may be an early sign of tendon or small joint involvement. Move the fingers passively to assess whether the problem is with the tendon or nerves, or in the joint.

- Assess wrist flexion and extension actively (e.g. by making the 'prayer' sign) and passively (see Figure 12).
- In patients where the history and examination suggest carpal tunnel syndrome perform Phalen's test (forced flexion of the wrists for 60 seconds) – in a positive test this reproduces the patient's symptoms.
- Assess power of the muscles innervated by the median and ulnar nerves. This can be done by abduction of the thumb, and finger spread, respectively.



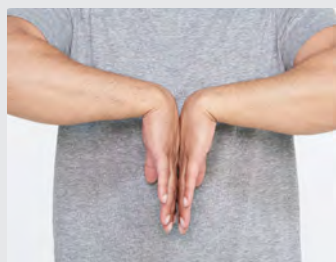### Function

- Ask the patient to grip your two fingers to assess power grip.
- Ask the patient to pinch your finger. This assesses pincer grip, which is very important functionally.
- Ask the patient to pick a small object such as a coin out of your hand or check their ability to undo buttons. This assesses pincer grip and function.

**FIGURE 12.**

**The 'prayer sign' assesses wrist flexion and extension:**

If the patient's history and examination suggest carpal tunnel syndrome, Phalen's test (forced flexion of the wrist for 60 seconds) may reproduce the patient's symptoms.



# EXAMINATION OF THE ELBOW

## Look

- Look from the front for the carrying angle, and from the side for flexion deformity.
- Look for scars, rashes, muscle wasting, rheumatoid nodules, psoriatic plaques, and swellings such as olecranon bursitis.

## Feel

- Using the back of your hand, feel the temperature across the joint and the forearm.
- Hold the forearm with one hand and, with the elbow flexed to 90°, palpate the elbow, feeling the head of the radius and the joint line with your thumb. If there is swelling, is it fluctuant? Synovitis is usually felt as a fullness between the olecranon and the lateral epicondyle.
- Palpate the medial and lateral epicondyles (for golfer's and tennis elbow respectively) and the olecranon process for tenderness and evidence of bursitis.

## Move

- Does the elbow extend fully and flex fully? Assess both actively and passively, and compare one side with the other. If there is limitation, note how severe it is.
- Assess pronation and supination, both actively and passively, feeling for crepitus.

## Function

- An important function of the elbow is to allow the hand to reach the mouth. Other functionally important movements (such as hands behind head) will have been assessed during the screening examination.

# EXAMINATION OF THE SHOULDER

## Look

- With the shoulder fully exposed, inspect the patient in stance from the front, from the side and from behind, checking for symmetry, posture, muscle wasting and scars.

## Feel

- Assess the temperature over the front of the shoulder (the glenohumeral joint).
- Palpate the bony landmarks for tenderness, starting at the sternoclavicular joint, then the clavicle, acromioclavicular joint, acromion process and around the scapula.
- Palpate the glenohumeral joint line – anterior and posterior.
- Palpate the muscle bulk of the supraspinatus, infraspinatus and deltoid muscles.



Watch the elbow examination video:

[www.versusarthritis.org/elbowexamination](http://www.versusarthritis.org/elbowexamination)



Watch the shoulder examination video:

[www.versusarthritis.org/shoulderexamination](http://www.versusarthritis.org/shoulderexamination)



**Move**

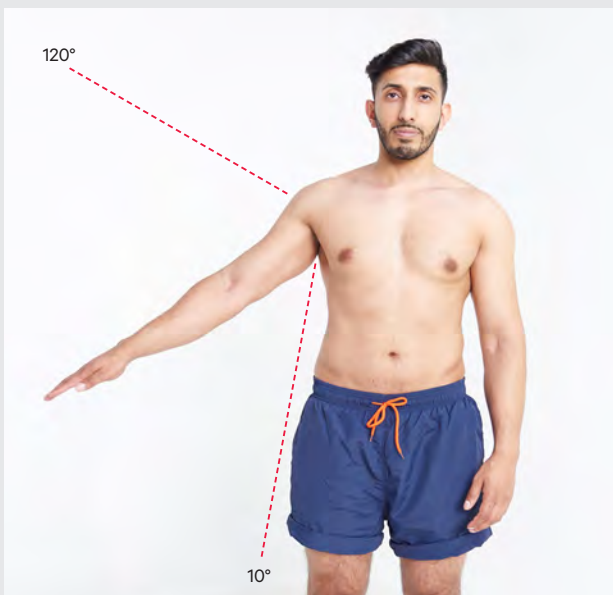- Ask the patient to put their hands behind their head to assess external rotation, and then behind their back to assess internal rotation, comparing one side with the other. If there is a restriction in the latter movement, describe how far the patient can reach – for example, to the lumbar, lower thoracic or mid-thoracic level.
- With the elbow flexed at 90° and tucked into the patient’s side, assess external rotation of the shoulder. Loss of external rotation may indicate adhesive capsulitis (“frozen shoulder”) or other glenohumeral joint problems.
- Ask the patient to raise their arms behind them and to the front. Assess flexion and extension.
- Ask the patient to abduct the arm to assess for a painful arc (between 10° and 120°) (see Figure 13). Can you passively take the arm further? Be sure to assess abduction from behind the patient and observe scapular movement. Restricted glenohumeral movement can be compensated for by scapular/thoracic movements.



**Function**

- Function of the shoulder includes getting the hands behind the head and back. This is important in washing, toileting and other self-care. If this has not been assessed during the screening examination, it should be done now.

**FIGURE 13.**  
Abduction of the arm to assess for a painful arc.




---



---



---



---



---



---



---



---

# EXAMINATION OF THE HIP



## Look

- With the patient standing, assess for muscle wasting (gluteal muscle bulk in particular).
- With the patient lying flat and face up, observe the legs, comparing one side with the other – is there an obvious flexion deformity of the hip suggesting osteoarthritis?
- If there is a suggestion of leg length disparity, assess true leg lengths using a tape measure. Measurements are taken from the anterior superior iliac crest to the medial malleolus of the ankle on the same side. Compare the measurements. In a fractured neck of femur, the leg is shortened and externally rotated. There may also be an indication of this on the patient's footwear with excessive wear on one heel.
- Check for scars overlying the hip.



## Feel

- Palpate over the greater trochanter for tenderness (suggestive of trochanteric bursitis) and in the groin for true hip joint problems.

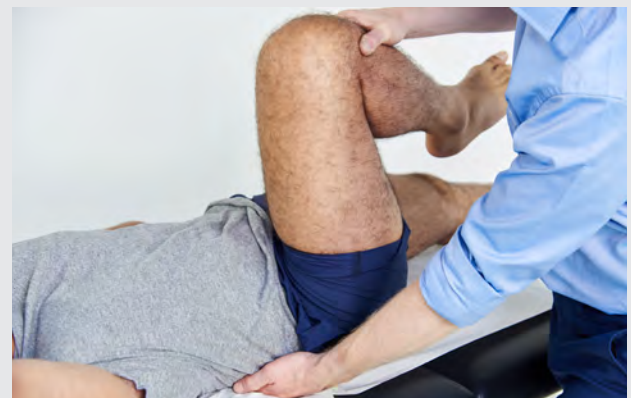

## Move

- With the knee flexed at 90°, assess full hip flexion, comparing one side with the other and watching the patient's face for signs of pain.
- Assess for a fixed flexion deformity of the hip by performing the Thomas test. Keep one hand under the patient's back to ensure that normal lumbar lordosis is removed. Fully flex one hip and observe the opposite leg (see Figure 14). If it lifts off the couch, then there is a fixed flexion deformity in that hip. (As the pelvis is forced to tilt a normal hip would extend allowing the leg to remain on the couch.)

**Figure 14.**

**Thomas test for fixed flexion deformity of the hip.** Keep one hand under the patient's back to ensure that there is no lumbar lordosis. Fully flex one hip. If the opposite leg lifts off the couch, there is a fixed flexion deformity. (As the pelvis tilts a normal hip would extend allowing the leg to remain on the couch.)







Watch the hip examination video:

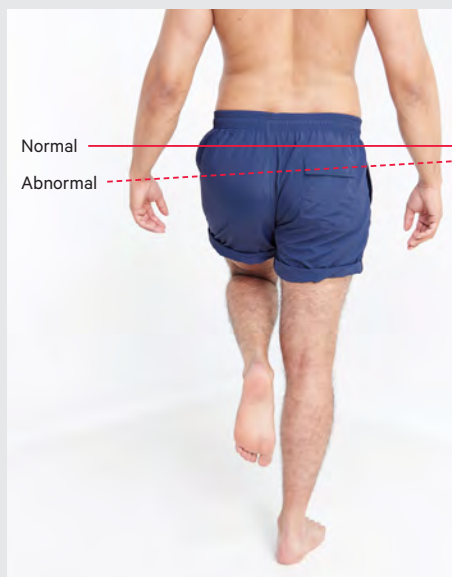
[www.versusarthritis.org/hipexamination](http://www.versusarthritis.org/hipexamination)

- With the hip and knee flexed at 90°, assess internal and external rotation of both hips. This is often limited in hip disease and internal rotation is frequently the first movement affected (see GALS screen).
- Assess the hip and proximal (gluteal) muscle strength by performing the Trendelenburg test. This involves the patient alternately standing on each leg alone. In a negative test, the pelvis remains level or even rises. In an abnormal test, the pelvis will dip on the contralateral side. (See Figure 15.).



### Function

- Ask the patient to walk – look for an antalgic or Trendelenburg gait. An antalgic gait simply means a painful gait, normally resulting in a limp. A Trendelenburg gait results from proximal muscle weakness and commonly results in a ‘waddling’ walk.



**Figure 15.**

**The Trendelenburg test assesses hip and gluteal muscle strength.**

In a normal test, the pelvis remains level. In an abnormal test, the pelvis dips on the contralateral side.

# EXAMINATION OF THE KNEE

## Look

- From the end of the couch and with the patient's legs straight, observe the knees, comparing one with the other for symmetry and alignment.
- Is the posture of the knee normal? Look for valgus deformity – where the leg below the knee is deviated laterally (knock-kneed) – and for varus deformity – where the leg below the knee is deviated medially (bow-legged).
- Check for a knee flexion deformity (distinguishing this from hip flexion deformity by examining hip movements as above).
- Check for muscle wasting of the quadriceps or scars.
- Look for redness suggesting inflammation or infection.
- Look for obvious swelling.
- Check for a rash suggesting psoriasis (usually on the extensor surface of the knee).

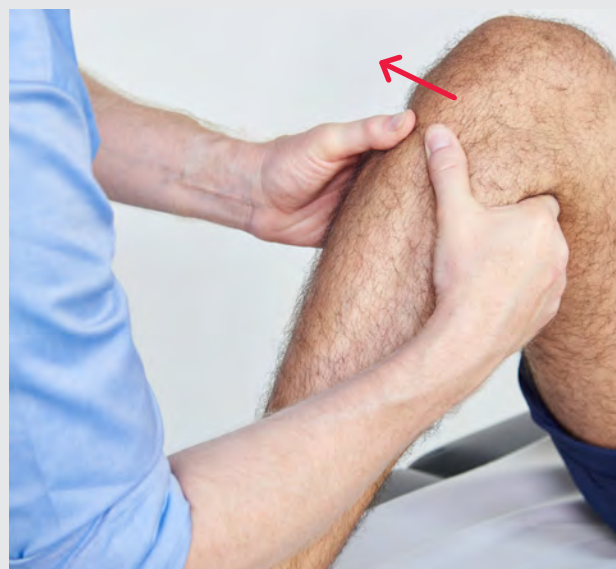**Note:** Popliteal swellings, varus and valgus deformities may be more apparent with the patient weight-bearing.

## Feel

- Using the back of your hand, feel the skin temperature, starting with the mid-thigh and comparing it to the temperature over the knee. Compare one knee to the other.
- Palpate for tenderness along the borders of the patella.
- With the knee flexed to 90°, palpate for tenderness and swelling along the joint line from the femoral condyles to the inferior pole of the patella, then down the inferior patella tendon to the tibial tuberosity.
- Feel behind the knee for a popliteal (Baker's) cyst.
- Assess for an effusion by performing either a sweep/bulge test or a patellar tap, as described in the section on the GALS screening examination (see Figures 8 and 9 on p.30-31).

**Figure 16.**

**Anterior draw test.** Place both hands around the upper tibia, with your thumbs over the tibial tuberosity and your index fingers tucked under the hamstrings to make sure these are relaxed. Stabilise the lower tibia with your forearm and gently pull the upper tibia forward. There should normally be a small degree of movement; more substantial movement suggests laxity of the anterior cruciate ligaments.





Watch the knee examination video:

[www.versusarthritis.org/kneeeexamination](http://www.versusarthritis.org/kneeeexamination)



## Move

- Ask the patient to flex the knee as far as possible to assess active movement. Making sure the patient is fully relaxed, assess passive movement. This is done by placing one hand on the knee (feeling for crepitus) and flexing the knee as far as possible, noting the range of movement. Assess full flexion and extension of the knees, comparing one to the other.
- With the knee flexed to 90°, check the stability of the knee ligaments. Look initially from the side of the knee, checking for a posterior sag or step-back of the tibia, suggesting posterior cruciate ligament damage.
- Perform an anterior draw test. Place both hands round the upper tibia, with your thumbs over the tibial tuberosity and index fingers tucked under the hamstrings to make sure these are relaxed. Stabilise the lower tibia with your forearm and gently pull the upper tibia forward

(see Figure 16). In a relaxed, normal patient there is normally a small degree of movement. More significant movement suggests anterior cruciate ligament laxity.

- Assess medial and lateral collateral ligament stability by flexing the knee to 15° and alternately stressing the joint line on each side. Place one hand on the opposite side of the joint line to that which you are testing and apply force to the lower tibia (see Figure 17). This may be done with the leg on the couch or with the lower tibia supported on the side of the examiners hip

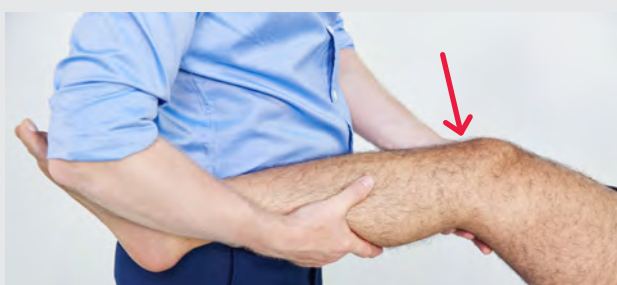
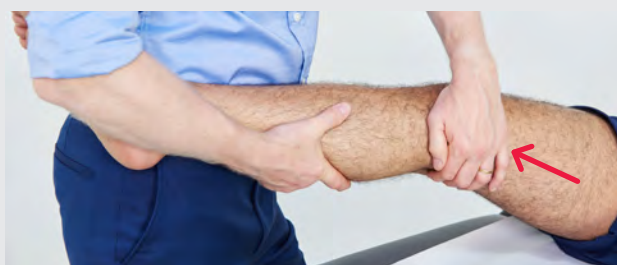
## Function

- Ask the patient to stand and then walk a few steps, looking again for a varus or valgus deformity (see Figure 18).

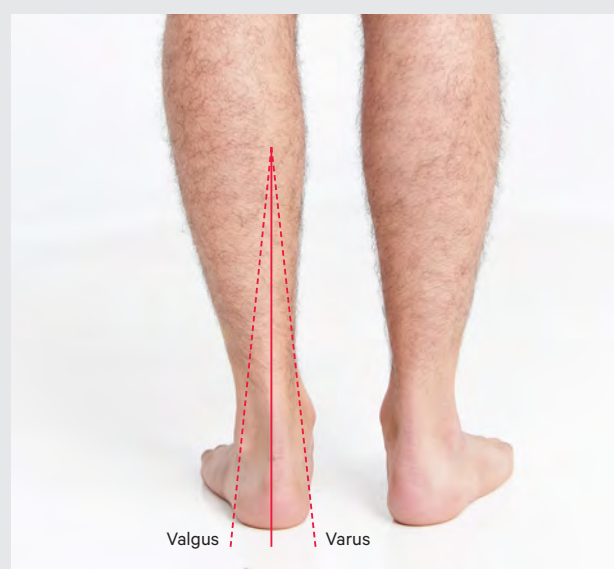**Figure 17.**

**Assessing medial and lateral collateral ligament stability.** With the patient's leg on the couch or supported on your pelvis, place one hand on the opposite side of the joint line to that which you are testing and alternately stress the joint line on each side by applying gentle force on the tibia.



**Figure 18.**

**With the patient standing, assess for a varus or valgus deformity.**



# EXAMINATION OF THE FOOT AND ANKLE



## Look

### With the patient sitting on the couch, their feet overhanging the end of it:

- Observe the feet, comparing one with the other for symmetry.
- Look specifically at the forefoot for nail changes or skin rashes, such as psoriasis.
- Look for alignment of the toes, evidence of hallux valgus of the big toe or subluxation (partial dislocation) of the joints.
- Look for clawing of the toes, joint swelling and callus formation which typically occurs over the metatarsophalangeal joints on the plantar aspect and over the dorsum and/or apex of the toes.
- Look at the underside or plantar surface for callus formation.
- Look at the patient's footwear. Check for abnormal or asymmetrical wearing of the sole or upper, for evidence of poor fit or the presence of special insoles.

### With the patient weight-bearing:

- Look again at the forefoot for toe alignment and whether they are in contact with the ground.
- Look at the midfoot for foot arch position (a low arch profile in a patient with normal joint movement should resolve when standing on tip toes).
- From behind, look at the hindfoot for Achilles tendon thickening or swelling.
- Look for normal alignment of the hindfoot (see Figure 18). Disease of the ankle or subtalar joint may lead to a varus or valgus deformity.



## Feel

- Assess the temperature over the forefoot, midfoot and ankle.
- Check for the presence of a peripheral pulse palpating the dorsalis pedis on the dorsum of the foot.
- Gently squeeze across the MTP joints, watching the patient's face for signs of pain or discomfort.
- Palpate the midfoot, the ankle and subtalar joints for tenderness.



## Move

- Assess, both actively and passively, movements of inversion and eversion at the subtalar joint, plus dorsi- and plantar flexion at the big toe and ankle joint checking for any restrictions and/or crepitus.
- Movement of the mid-tarsal joints can also be performed by fixing the heel with one hand and, with the other hand, passively inverting and everting the forefoot



## Function

- If not already done, assess the patient's gait, watching for the normal cycle of heel strike, stance, and toe-off, speed of walking and turning.



Watch the foot and ankle examination video:

[www.versusarthritis.org/footandankleexamination](http://www.versusarthritis.org/footandankleexamination)

# EXAMINATION OF THE SPINE

## Look

- Observe the patient standing. Look initially from behind the patient for any obvious muscle wasting, asymmetry, or scoliosis of the spine.
- Look from the side for normal cervical lordosis, thoracic kyphosis, and lumbar lordosis.

## Feel

- Feel down the spinal processes from the top of the neck to the sacrum and over the sacroiliac joints for alignment and tenderness.
- Palpate the paraspinal muscles for tenderness.

## Move

- Assess lumbar flexion and extension by placing two or three fingers over the lumbar spine. Ask the patient to bend to touch their toes. Your fingers should move apart during flexion and back together during extension (see Figure 10 on p.32).
- Ask the patient to run each hand in turn down the outside of the adjacent leg to assess lateral flexion of the spine.
- Next, assess the cervical spine movements. Ask the patient to: tilt their head to each side, bringing the ear towards the adjacent shoulder (lateral flexion); turn their head to look over each shoulder



Watch the spine examination video:

[www.versusarthritis.org/spineexamination](http://www.versusarthritis.org/spineexamination)

(rotation); bring their chin towards their chest (flexion); and tilt their head backwards (extension). As highlighted in the GALS screen, lateral flexion is usually the first movement to be restricted.

- With the patient sitting on the edge of the couch to fix their pelvis and their arms crossed in front of them, assess thoracic rotation (with your hands on the patient's shoulders to guide the movement) (see Figure 19).
- With the patient lying as flat as possible, perform straight leg raising (see Figure 20). Dorsiflexion of the foot with the leg raised may exacerbate the pain from a nerve root entrapment or irritation such as that caused by a prolapsed intervertebral disc.

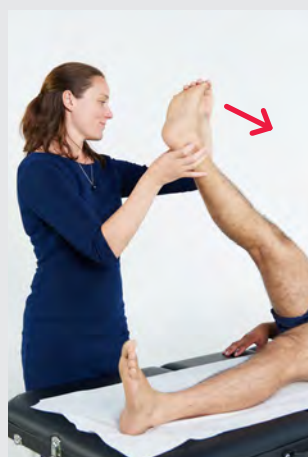


## Function

- A brief neurovascular examination should be carried out including assessment of upper and lower limb reflexes, dorsiflexion of the big toe, and assessment of peripheral pulses. If there has been any indication from the history of a relevant abnormality, a full neurological and vascular assessment – including sensation, tone and power – should also be made.

**Figure 19.**

With the patient seated on the couch to fix the pelvis, assess thoracic rotation.



**Figure 20.**

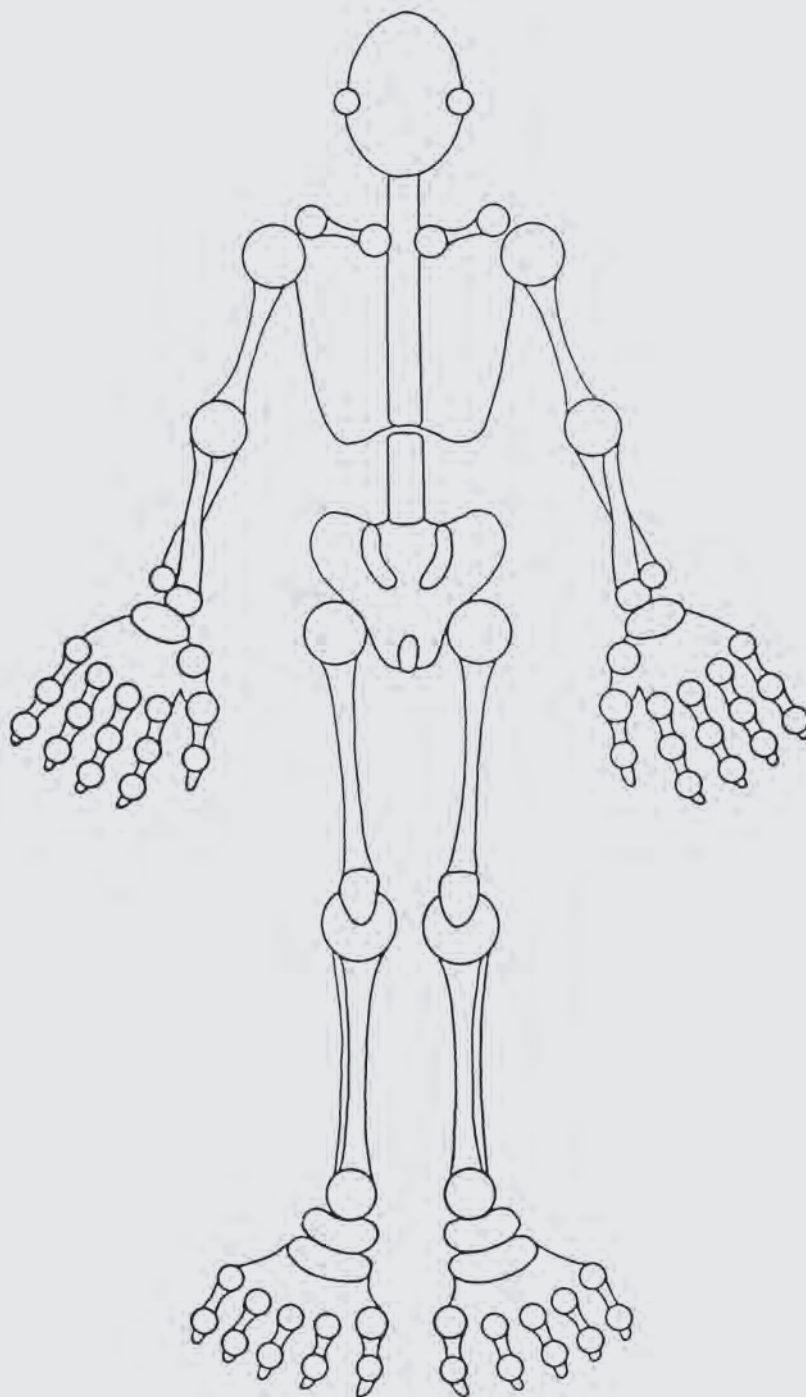
Dorsiflexion of the foot with the leg straight and raised may exacerbate pain from a nerve root entrapment or prolapsed disc.

# RECORDING THE FINDINGS FROM THE REGIONAL EXAMINATION


The positive and significant negative findings of the REMS examination are usually documented longhand in the notes. You may find it helpful to document joint involvement on a homunculus such as the one shown in Figure 21. In electronic patient records there is often a similar homunculus for ease of documentation. The total number of tender and swollen joints can be used for calculating a Disease Activity Score (DAS) – these are useful in monitoring disease severity and response to treatment over time.



This section contains a large grey rectangular area intended for notes. It features a small icon in the top-left corner depicting a document with a pencil, indicating a writing or editing function. Below the icon are ten horizontal lines spaced evenly down the page, providing a template for longhand notes.



**Figure 21.**  
Printed homunculus for annotation.



# 05. INVESTIGATIONS



**50 IMAGING OF BONES AND JOINTS**

**51 BLOOD TESTS**

**51 SYNOVIAL FLUID ANALYSIS**

# INVESTIGATIONS

There are three main types of investigations that can be used to further classify musculoskeletal presentations:

- imaging of bones and joints
- blood tests
- synovial fluid analysis.

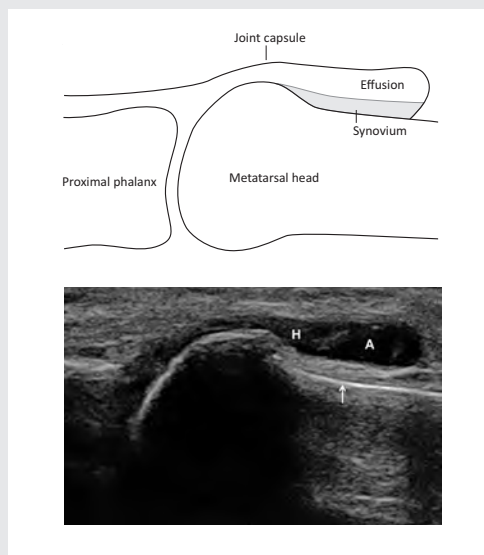
This guide aims to outline the methods you might use in the initial clinical assessment and so a comprehensive overview of investigations is not possible here. However, this section gives a brief introduction to some of the investigations that might be considered.

# IMAGING OF BONES AND JOINTS

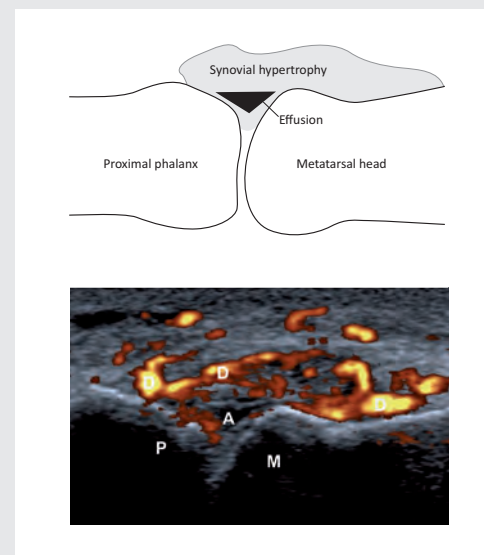
A plain x-ray of the affected joint is one of the most useful investigations. Changes that occur on plain x-ray can be characteristic of specific musculoskeletal diseases such as rheumatoid arthritis, osteoarthritis and gout. Most changes occur over a prolonged period and x-rays can therefore provide a useful historical record.

Ultrasound is becoming increasingly widely used, particularly in identifying early joint inflammation (see Figures 22, 23), although it doesn't necessarily add significantly to the clinical assessment in patients with clinical signs. Other investigations – including magnetic resonance imaging (MRI), computerised tomography (CT) scanning, isotope bone scans and dual-energy x-ray absorptiometry (DEXA) scans (for osteoporosis) – all have an important role.

**Figure 22.** Grey-scale scan of early osteoarthritis of the 1st metatarsophalangeal joint, showing a small anechoic effusion with some hypoechoic synovial thickening within the joint capsule. (A = anechoic effusion; H = hypoechoic synovium).



**Figure 23.** Power Doppler scan of the 1st metatarsophalangeal joint, showing a small anechoic effusion surrounded by a grade 3 Doppler signal that represents florid synovitis. (A = anechoic effusion; D = Doppler signal; M = metatarsal head; P = proximal phalanx).



# BLOOD TESTS

Blood tests can be useful in indicating the degree of inflammation and in monitoring response to therapy as well as helping to achieve a diagnosis:

- **The erythrocyte sedimentation rate (ESR)** is one of the best-known inflammatory markers and indicates what has been happening over the last few days or longer. It is non-specific and influenced by many things including anaemia.
- **C-reactive protein** responds more rapidly to changes in inflammation – normally within days.
- **Serum uric acid** may be raised in gout, although it may be unreliable during an acute episode.
- Increased titres of a number of **autoantibodies** may be found, although their significance is not always clear. Tests for **rheumatoid factor** and **anti-CCP (cyclic citrullinated peptide)** antibody, for example, are both often strongly positive in patients with rheumatoid arthritis. However, rheumatoid factor may also be positive in other disease states and in the elderly, and is therefore not highly specific.

It is also important to consider infection as a cause of an arthropathy, particularly in the case of a single joint – blood cultures for infection should be taken even if there is no fever.

# SYNOVIAL FLUID ANALYSIS

Obtaining a sample of synovial fluid for analysis is an important skill to learn and is vital to perform in order to exclude infection of a joint, which would normally present with an acute monoarthritis with systemic symptoms. Synovial fluid should be sent for culture and gram staining. If gout or other crystals are considered as a cause of the problem, the fluid is examined for crystals under a polarizing light microscope.



---

---

---

---

---

---

---

---

---

---



# 06. CONCLUSION

- 54** **APPENDIX 1:  
REVISION CHECKLISTS**
- 58** **APPENDIX 2:  
THE CORE SET OF REGIONAL  
MUSCULOSKELETAL EXAMINATION  
SKILLS APPROPRIATE FOR A MEDICAL  
STUDENT AT THE POINT  
OF QUALIFICATION**
- 59** **APPENDIX 3: PGALS AND PREMS**
- 60** **BIBLIOGRAPHY**
- 60** **ENDORSEMENTS**

# APPENDIX 1: REVISION CHECKLISTS

## History Taking (p.16)

### Symptoms

- Pain
- Pain
- Stiffness
- Swelling
- Pattern of joint involvement

### Evolution

- Acute or chronic?
- Associated events
- Response to treatment

### Involvement of other systems

- Skin, eye, lung or kidney symptoms?
- Malaise, weight loss, fevers, night sweats?

### Impact on patient's lifestyle

- Patient's needs/aspirations
- Ability to adapt to functional loss

## GALS Screening Questions (p.26)

- Do you have any pain or stiffness in your muscles, joints or back?
- Can you dress yourself completely without any difficulty?
- Can you walk up and down stairs without any difficulty?

## GALS Screening Examination (p.28)

### Gait

- Observe gait for symmetry and smoothness of movement, normal stride length and ability to turn normally
- Observe patient in anatomical position

### Arms

- Observe movement – hands behind head, arms out straight, and normal pronation/supination of forearm
- Observe backs of hands and wrists for swelling/deformity
- Observe palms for muscle wasting
- Assess power grip and grip strength
- Assess fine precision pinch
- Squeeze MCP joints

### Legs

- Assess full flexion and extension, checking for crepitus during passive knee flexion
- Assess internal rotation of hips
- Assess for a knee effusion/swelling/deformity
- Inspect feet for calluses
- Squeeze MTP joints

### Spine

- Inspect spine for muscle bulk, level iliac crests, normal kyphosis and lordosis, and for scoliosis
- Assess lateral flexion of neck
- Assess lumbar spine movement

**REMS General Principles (p.34)****Introduction**

- Introduce yourself
- Gain verbal consent to examine

**Look for:**

- Scars
- Swellings
- Rashes
- Muscle wasting

**Feel for:**

- Temperature
- Swellings
- Tenderness

**Move**

- Full range of movement – active and passive
- Restriction – mild, moderate or severe?

**Function**

- Functional assessment of joint

**Examination of the hand and wrist (p.36)**

- Introduce yourself/gain consent to examine
- Inspect hands (palms and backs) for muscle wasting, skin and nail changes
- Check wrist for carpal tunnel release
- Feel for radial pulse, tendon thickening and bulk of thenar and hypothenar eminences
- Assess median, ulnar and radial nerve sensation
- Assess skin temperature
- Squeeze MCP joints
- Bimanually palpate swollen or painful joints, including wrists
- Look and feel along ulnar border
- Assess full finger extension and full finger tuck
- Assess wrist flexion and extension – active and passive
- Assess median and ulnar nerve power
- Assess function: grip and pinch, picking up small object
- Perform Phalen's test (if suggestion of carpal tunnel syndrome)

**Examination of the elbow (p.38)**

- Introduce yourself/gain consent to examine
- Look for scars, swellings or rashes
- Assess skin temperature
- Palpate over head of radius, joint line, medial and lateral epicondyles
- Assess full flexion and extension, pronation and supination – actively and passively
- Assess function – e.g. hand to nose or mouth

# APPENDIX 1: REVISION CHECKLISTS

## Examination of the shoulder (p.38)

- Introduce yourself/gain consent to examine
- Inspect shoulders from in front, from the side and from behind
- Assess skin temperature
- Palpate bony landmarks and surrounding muscles
- Assess movement and function: hands behind head, hands behind back
- Assess (actively and passively) external rotation, flexion, extension and abduction
- Observe scapular movement

## Examination of the hip (p.40)

- Introduce yourself/gain consent to examine

### With the patient lying on couch:

- Look for flexion deformity and leg length disparity
- Check for scars
- Feel the greater trochanter for tenderness
- Assess full hip flexion, internal and external rotation
- Perform the Thomas test

### With the patient standing:

- Look for gluteal muscle bulk

### Perform the Trendelenburg test

- Assess the patient's gait

## Examination of the knee (p.42)

- Introduce yourself/gain consent to examine

### With the patient lying on couch:

- Look from the end of the couch for varus/valgus deformity, muscle wasting, scars and swellings
- Look from the side for fixed flexion deformity
- Assess skin temperature
- With the knee slightly flexed palpate the joint line and the borders of the patella
- Feel the popliteal fossa
- Perform a patellar tap and cross fluctuation (bulge sign)
- Assess full flexion and extension (actively and passively)
- Assess stability of knee ligaments medial and lateral collateral – and perform anterior draw test

### With the patient standing:

- Look again for varus/valgus deformity and popliteal swellings
- Assess the patient's gait



**Examination of the foot and ankle (p.44)**

- Introduce yourself/gain consent to examine

**With the patient lying on couch:**

- Look at dorsal and plantar surfaces of the foot
- Assess skin temperature
- Palpate for peripheral pulses
- Squeeze the MTP joints
- Palpate the midfoot, ankle joint line and subtalar joint
- Assess movement (actively and passively) at the subtalar joint (inversion and eversion), the big toe (dorsi- and plantar flexion), the ankle joint (dorsi- and plantar flexion) and mid-tarsal joints (passive rotation)
- Look at the patient's footwear

**With the patient standing:**

- Look at the forefoot, midfoot (foot arch) and the hindfoot
- Assess the gait cycle (heel strike, stance, toe-off)

**Examination of the spine (p.45)**

- Introduce yourself/gain consent to examine

**With the patient standing:**

- Inspect from the side and from behind
- Palpate the spinal processes and paraspinal muscles
- Assess movement: lumbar flexion and extension and lateral flexion; cervical flexion, extension, rotation and lateral flexion

**With the patient sitting on couch:**

- Assess thoracic rotation

**With the patient lying on couch:**

- Perform straight leg raising and dorsiflexion of the big toe
- Assess limb reflexes




---



---



---



---



---



---

# APPENDIX 2: THE CORE SET OF REGIONAL MUSCULOSKELETAL EXAMINATION SKILLS (COADY ET AL, 2004)

## A student at the point of qualification should be able to:

- 1 detect the difference between bony and soft tissue swelling
- 2 elicit tenderness around a joint
- 3 elicit temperature around a joint
- 4 detect synovitis
- 5 understand the difference between active and passive movements
- 6 perform passive and active movements at all relevant joints
- 7 detect a loss of full extension and a loss of full flexion
- 8 assess gait
- 9 correctly use the terms 'varus' and 'valgus'
- 10 assess limb reflexes routinely – when examining the spine and in other relevant circumstances
- 11 have an understanding of the term 'subluxation'
- 12 where appropriate, examine neurological and vascular systems when assessing a problematic joint (check for intact sensation and peripheral pulses)
- 13 assess leg length with a tape measure when assessing for a real leg length discrepancy
- 14 make a qualitative assessment of movement (features such as cog-wheeling)
- 15 assess the median and ulnar nerves
- 16 be able to localise tenderness within the joints of the hand (palpate each small joint of the hand if necessary)
- 17 assess power grip
- 18 assess pincer grip in the hand
- 19 make a functional assessment of the hand such as holding a cup
- 20 correctly use the term 'Heberden's nodes'
- 21 be able to perform Phalen's test
- 22 detect a painful arc and frozen shoulder
- 23 make a functional assessment of the shoulder (can the patient put their hands behind their head and back?)
- 24 perform external/internal rotation of the shoulder with the elbow flexed to 90° and held in against the patient's side
- 25 examine a patient's shoulder from behind for scapular movement
- 26 assess the acromioclavicular joint (by palpation alone)
- 27 palpate for tenderness over the epicondyles of the elbow
- 28 palpate for tenderness over the greater trochanter of the hip
- 29 perform internal and external rotation of the hip with it flexed to 90°
- 30 perform Trendelenburg test
- 31 perform the Thomas test
- 32 detect an effusion at the knee
- 33 perform a patellar tap
- 34 demonstrate cross-fluctuation or the bulge sign when looking for a knee effusion
- 35 test for collateral ligament stability in the knee
- 36 use the anterior draw test to assess anterior cruciate ligament stability in the knee
- 37 examine the soles of a patient's feet
- 38 recognise hallux valgus, claw and hammer toes
- 39 assess a patient's feet with them standing
- 40 assess for flat feet (including the patient standing on tip toes)
- 41 recognise hindfoot/heel pathologies
- 42 assess plantar and dorsiflexion of the ankle
- 43 assess movements of inversion and eversion of the foot
- 44 assess the subtalar joint
- 45 perform a lateral squeeze across the metatarsophalangeal joints
- 46 assess flexion/extension of the big toe
- 47 examine a patient's footwear
- 48 palpate the spinal processes
- 49 assess lateral and forward flexion of the lumbar spine (using fingers, not tape measure)
- 50 assess thoracic rotation with the patient sitting

# APPENDIX 3: PGALS AND PREMS

pGALS follows the same approach as GALS but with additions as listed in the table below. These were added as adult GALS missed significant abnormalities when tested on school-aged children.

Movement	Purpose
Walk on heels and then on tiptoes	Assesses foot and ankles, gives information about balance and co-ordination
Open mouth and insert 3 of the child's own fingers into their mouth	Assess temporomandibular joint opening and symmetry
Reach up and touch the sky	Assess full extension at the elbow joint and rotation at the shoulder joints
Look at the ceiling	Assesses cervical spine extension

pREMS follows the same approach as REMS with 'look, feel, move' but with the addition of 'measure' in certain regions (for example measurement of leg length or thigh girth). The table below lists suggestions for examinations (for example, neurological or muscle strength) that should be conducted in addition to those included in the adult REMS.

## pREMS additional features

### Hand and wrist

- Tinel's test (carpal tunnel syndrome)
- Nailfold capillaroscopy
- Hypermobility

### Elbow

- Muscle power
- Peripheral nerves
- Peripheral pulses
- Hypermobility
- Entheses

### Shoulder

- Muscle power
- Peripheral nerves
- Peripheral pulses
- Hypermobility

### Spine

- 1-leg standing spine extension test

### Hip

- Gower's test
- Entheses
- Muscle power
- Hypermobility

### Knee

- Clarke's test
- Patellar tracking
- Thigh-foot angle
- Hamstring tightness

- Iliotibial band tightness

- Knock-knee/bow-leg assessment

- Thigh girth measurement

- Muscle power
- Hypermobility

- Normal development of leg alignment

### Foot and ankle

- Thigh-foot angle

- Hypermobility
- Entheses

- Muscle power

- Nailfold capillaroscopy

### Gait

- Limb and trunk proportions

- Jaw profile

### Hypermobility and inherited collagen disorders

- Beighton score

- Hypermobility

- Habitus

- Skin elasticity

- Sclerae

### Entheses

- Knee

- Foot and ankle



Video demonstrations of pGALS and pREMS are available at Paediatric Musculoskeletal Matters:

[pmmonline.org/](http://pmmonline.org/)

# BIBLIOGRAPHY

Coady D, Walker D and Kay L, 2004. Regional Examination of the Musculoskeletal System (REMS): a core set of clinical skills for medical students. *Rheumatology*, 43(5), pp.633-639. <https://academic.oup.com/rheumatology/article/43/5/633/1788669> **Accessed: 10/07/2019**

Department of Health, 2006. The musculoskeletal services framework. A joint responsibility: doing it differently. [https://webarchive.nationalarchives.gov.uk/20130124073659/http://www.dh.gov.uk/prod\\_consum\\_dh/groups/dh\\_digitalassets/@dh/@en/documents/digitalasset/dh\\_4138412.pdf](https://webarchive.nationalarchives.gov.uk/20130124073659/http://www.dh.gov.uk/prod_consum_dh/groups/dh_digitalassets/@dh/@en/documents/digitalasset/dh_4138412.pdf)

**Accessed: 10/07/2019**

Doherty M, Dacre J, Dieppe P and Snaith M, 1992. The 'GALS' locomotor screen. *Annals of the Rheumatic Diseases*, 51(10), pp.1165-1169. <https://ard.bmj.com/content/51/10/1165.short> **Accessed: 10/07/2019**

Foster HE, Kay LJ, Friswell M, Coady D and Myers A, 2006. Musculoskeletal screening examination (pGALS) for school age children based on the adult GALS screen. *Arthritis Care & Research: Official Journal of the American College of Rheumatology*, 55(5), pp.709-716. <https://onlinelibrary.wiley.com/doi/full/10.1002/art.22230> **Accessed: 10/07/2019**

Foster H, Kay L, May C. and Rapley T, 2011. Pediatric regional examination of the musculoskeletal system: A practice and consensus based approach. *Arthritis care & research*, 63(11), pp.1503-1510. <https://onlinelibrary.wiley.com/doi/full/10.1002/acr.20569> **Accessed:10/07/2019**

Global Burden of Disease Collaborative Network. Global Burden of Disease Study 2017 (GBD 2017) Results. Institute for Health Metrics and Evaluation (IHME), Seattle, 2018.

Vos T, Abajobir AA, Abate KH, Abbafati C, Abbas KM, Abd-Allah F, Abdulkader RS, Abdulle AM, Abebo TA, Abera SF and Aboyans V, 2017. Global, regional, and national incidence, prevalence, and years lived with disability for 328 diseases and injuries for 195 countries, 1990–2016: a systematic analysis for the Global Burden of Disease Study 2016. *The Lancet*, 390(10100), pp.1211-1259. <https://www.sciencedirect.com/science/article/pii/S0140673617321542> **Accessed:10/07/2019**

World Health Organization, 2016. International Statistical Classification of Diseases and Related Health Problems, 10th revision. <https://icd.who.int/browse10/2016/en> **Accessed: 10/07/2019**

# ENDORSEMENTS



This guide is endorsed by the British Society for Rheumatology. Rheumatology is a fun, friendly and rewarding specialty, with a strong focus on teamwork and cohesiveness across the entire multi-disciplinary team. Rheumatologists work closely with other specialties to solve difficult diagnoses and often have an active role in research; trainees have plenty of opportunities to get involved in education, clinical governance and management.

The British Society for Rheumatology is there for you from the start of your career in the specialty. They'll help you progress, collaborate and innovate to deliver the best care for your patients through a wide range of courses, conferences, fellowships, bursaries and awards, as well as a mentoring programme and peer-reviewed eLearning lectures and modules.

To find out more about how they can support you, go to **[www.rheumatology.org.uk/membership](http://www.rheumatology.org.uk/membership)**.



British  
Orthopaedic  
Association

This guide is endorsed by The British Orthopaedic Association. The British Orthopaedic Association supports 5,000 members throughout the UK and internationally. By bringing together all those working in trauma and orthopaedic surgery they aim to provide national leadership and a unifying focus supporting their members to deliver excellence in patient care.

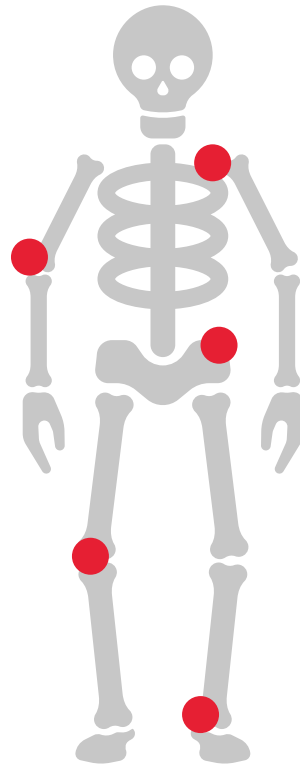
Being a trauma and orthopaedic surgeon is an extremely rewarding career: there are few areas in medicine where you have the opportunity to transform people's lives, whether you are putting them back together after severe trauma, or you are giving someone back their independence by relieving the pain from an arthritic joint. A career in trauma and orthopaedics combines theoretical knowledge with practical skills, but also involves an interface with technology, industry and a multidisciplinary team unlike any other specialty.

To find out more about how they can support you, go to **[www.boa.ac.uk](http://www.boa.ac.uk)**

**THIS GUIDE,  
TOGETHER  
WITH THE  
ACCOMPANYING  
VIDEOS, HAS  
DOCUMENTED THE  
CORE SKILLS OF  
MUSCULOSKELETAL  
EXAMINATION AND  
HISTORY TAKING**

However, the importance of guided clinical teaching and the development of clinical reasoning skills cannot be overemphasised. It is only through real-life clinical practice that competence and confidence in musculoskeletal clinical examination can be achieved.

We hope that you will find the guide valuable for reference and revision, but Versus Arthritis is always delighted to receive feedback at: **professionalengagement@versusarthritis.org**





A series of horizontal lines for writing, filling most of the page below the icon.



## FOR YOU...

- Join our professional network and become part of a growing community working together to change the face of MSK care. We'll keep you connected with the latest developments in MSK health and care, you'll receive bulletins containing practical tips, and development opportunities as well as the latest Versus Arthritis patient information.
- If you're looking to gain some hands-on, practical training in MSK then check out our Core Skills in Musculoskeletal Care. Core Skills is designed to help you feel confident and knowledgeable in managing patients with MSK conditions. Our e-learning is free to access, and you can build on this with some hands-on learning at one of our practical workshops running across the UK.
- Through our MSK champions programme we are aiming to create leaders of change who are committed to driving improvements in musculoskeletal care. Keep your eye on our website for dates for applications for the next cohort.

Find out more at

**[www.versusarthritis.org/about-arthritis/healthcare-professionals/](http://www.versusarthritis.org/about-arthritis/healthcare-professionals/)**

## FOR YOUR PATIENTS...

- Order or download patient information leaflets free of charge
- Encourage your patients to call the free Versus Arthritis helpline
- Signpost to our arthritis virtual assistant, a 24/7 tool that provides fast, easy to access information
- Explore our online community which will connect your patients with real people who share the same everyday experiences
- Connect to local groups and find out what's going on where your patients are

Find out more at

**[www.versusarthritis.org/get-help/](http://www.versusarthritis.org/get-help/)**

**HEALTHCARE  
PROFESSIONALS  
VERSUS  
ARTHRITIS**